

ASSOCIATION OF GENDER TO MANDIBULAR SECOND MOLARS WITH SINGLE FUSED CANAL: A RETROSPECTIVE STUDY

¹Rukhsaar Gulzar, ²Manish Ranjan, ³J Mahalakshmi

¹Department of Conservative Dentistry and Endodontics, Saveetha Dental College and Hospital, Saveetha Institute of Medical and Technical Science, Saveetha University, 162, Poonamallee High Road Chennai, India
Email: rukhsaar.gulzar23@gmail.com

²Reader Department of Conservative Dentistry and Endodontics, Saveetha Dental College and Hospital, Saveetha Institute of Medical and Technical Science, Saveetha University, 162, Poonamallee High Road Chennai, India Email ID: manish@saveetha.com

³Senior Lecturer Department of Conservative Dentistry and Endodontics, Saveetha Dental College and Hospital, Saveetha Institute of Medical and Technical Science, Saveetha University, 162, Poonamallee High Road Chennai, India Email ID: mahalakshmi.sd@saveetha.com

Article Info

Volume 82

Page Number: 17281 - 17288

Publication Issue:

January - February 2020

Article History

Article Received: 18 October 2019

Revised: 14 November 2019

Accepted: 22 December 2019

Publication: 29 February 2020

Abstract:

The occurrence of aberrant anatomy is one of the causes of endodontic failures when they are not detected accurately. Hence understanding these anomalies is highly important for a dental practitioner. The present retrospective study was conducted to analyse the incidence of a single fused canal in mandibular second molars and its association with gender. Data was obtained from the database of the institute and the preoperative and obturation radiographs were evaluated. The details were entered in an excel sheet and a descriptive statistical analysis and a chi square test by SPSS. The results of the present study showed a 1.6% chance of occurrence of a single fused root with a single canal in a mandibular second molar with a higher predilection for females. These results are statistically significant with a p value of 0.012. From a clinical point of application, a complete examination from multiple angled radiographs and three dimensional assessment must be conducted when an unusual anatomic form is encountered. This will reveal accurate details and will help in preventing iatrogenic errors which often lead to the failure of endodontic treatment.

Keywords: Aberrant Anatomy; C Shaped Canal; Canal Morphology; Mandibular Second Molar; Single Fused Canal.

I. INTRODUCTION

The success of a root canal therapy is primarily dependent on the accurate diagnosis and the complete elimination of bacteria from all the canals. This is possible only when one is able to accurately locate all the canals and negotiate its morphology from the coronal to the apical third. Variation in the anatomy of these canals is an occurrence that can be

noticed in all groups of teeth. Multi-rooted teeth pose a persistent challenge for accurate diagnosis during endodontic therapy by way of its variation in root canal anatomy.(Malagnino, Gallottini and Passariello, 1997) While focusing on locating extra canals, apical ramifications, lateral canals, a clinician must not ignore the possibility of a single fused canal. A thorough knowledge of such variations is

highly imperative, particularly in relation to the location, number and shape of the canals.

The general anatomic configuration of a mandibular second molar is that of two roots, one mesial and one distal. According to Weine, the mandibular second molar exhibits greater anatomical variations when compared to all the other molar teeth. (Weine, Pasiewicz and Ted Rice, 1988; Weine, 1998) The most common anomaly noticed in the mandibular second molar is that where the roots get fused to form a single root with varying internal anatomy which is often in C shape configuration. (Fan *et al.*, 2008) When one root is present, the root canal system may present a broad root canal, two canals that may or may not join or a c-shaped canal. (Weine, 1998)

The difference in the morphological variance in the root and the root canal system among the mandibular molars is a challenge for the practitioners during the endodontic treatment, particularly in the diagnosis so that no canal is missed. Vertucci type I canal configuration where there is a single canal can often be observed in mandibular second molars as reported in a study by Weine et al who found 13% chance of a single canal configuration in mandibular second molars; there by highlighting the importance of studying the probability of occurrence of various root canal morphology. (Weine, Pasiewicz and Ted Rice, 1988; Cimilli *et al.*, 2005)

The present retrospective study was conducted with the aim of evaluating the incidence of a single root with a single fused canal in the mandibular second molar and to study its association with gender.

The following were the objectives of the study:

1. To evaluate the incidence of a single root with a single fused canal in mandibular second molars

2. To study if there is any association of the occurrence of a single root with a single fused canal in mandibular second molar with different gender groups

II. MATERIALS AND METHOD

The present retrospective study was conducted at the department of Conservative Dentistry and Endodontics at Saveetha Dental College in Chennai. For the purpose of data collection, all the preoperative radiographs and obturation radiographs of endodontically treated mandibular second molars between the month of June 2019 and April 2020 were obtained from the college database along with the demographic details of the patient. An excel sheet was tabulated for the same which recorded the age, gender and the canal configuration of the mandibular second molar of the patient. Two reviewers were involved in the evaluation of the radiographs to minimize the bias. The data was evaluated in SPSS 2.0 IBM software and a descriptive statistical analysis was performed to obtain the frequency and percentage. A chi square test was done to find out if there is any association of the occurrence of a single root with a single fused canal in a mandibular second molar with gender. A p value of <0.05 in the chi square test was considered as statistically significant.

III. RESULTS AND DISCUSSION

A total of 509 mandibular second molars were evaluated. Upon analysis, out of the 509 mandibular second molars, 8 (1.6%) had the configuration of a single fused root with a single canal (Fig 1). When comparing the gender, seven (87.50%) of these eight cases were observed in females and only one (12.50%) was observed in male. The chi square value for the chi square test was 6.239 and the p value was 0.012 which was <0.05, making it statistically significant. Single fused canals in mandibular second

molars had a predilection for females as compared to males (Fig 2).

Previously our team had conducted numerous clinical trials (Ramamoorthi, Nivedhitha and Divyanand, 2015; Nasim *et al.*, 2018; Janani, Palanivelu and Sandhya, 2020), in vitro studies (Ramanathan and Solete, 2015; Nandakumar and Nasim, 2018; Teja, Ramesh and Priya, 2018; Rajendran *et al.*, 2019; Siddique *et al.*, 2019) and surveyed (Manohar and Sharma, 2018; Jose, P. and Subbaiyan, 2020) and reviewed various aspects of endodontics and conservative dentistry (Teja, K.V. and Ramesh, S., 2019; Noor, S Syed Shihaab and Pradeep, 2016; Kumar and Delphine Priscilla Antony, 2018; Ravinthar and Jayalakshmi, 2018; R, Rajakeerthi and Ms, 2019) over the past five years. Now we are focusing on retrospective studies, the idea for which has stemmed from the current interest in our community. Acknowledging the importance of studying anomalies in root canal morphology, this retrospective study was conducted to highlight the incidence of a particular anomaly of single root with a single fused canal in mandibular second molars.

It was Cooke and Cox in 1979 who first reported in literature the occurrence of C shaped cross sectional configuration in mandibular second molars.(Cooke, Groves Cooke and Cox, 1979) Though mandibular second molar is the one where C shaped canals are most commonly found, it can also be observed in maxillary molars, mandibular third molars and mandibular premolars. A variation in the location and number of canals present in the C shaped configuration can be observed as the canal courses from the coronal third to the apical third.(Fernandes, de Ataide and Wagle, 2014)

The Hertwig's epithelial sheath determines the shape and number of roots. It bends in a horizontal plane

below the cemento-enamel junction and fuses in the center leaving openings for roots. (Orban and Mueller, 1929)The main cause for C shaped roots which contain C shaped canal is the failure of the Hertwig's epithelial root sheath to fuse on the lingual or buccal root surface. The coalescence because of deposition of the cementum with time may also be the cause for C shaped roots. (Manning, 1990)

Many different methods have been used to study this specific root canal configuration. Histological sections, clearing and micro computed tomography have been used in ex vivo studies white spiral CT, cone beam CT and radiographic techniques have been used in in vivo studies. . Previous studies reveal that when compared to western countries, there is a considerably higher prevalence of C-shaped configurations in mandibular second molars in East Asian populations.Further, there was a higher prevalence in females (16.5%) as compared to males (10.4%) which was statistically significant in the global sample ($p < 0.05$). (Zuben *et al.*, 2017)

Various classifications were put forth to better understand the variation in the root canal anatomy of C shaped canals which do not have a fixed spatial relation. In one such classification given by Fan *et al.*, Type 4 configuration has been described as cross section showing only one round oval canal.(Fan, Cheung, Fan, Gutmann and Bian, 2004; Fan, Cheung, Fan, Gutmann and Fan, 2004) Fava *et al.* has reported the presence of one single root and one root canal in all second molars of the same patient which is a rare occurrence.(Fava *et al.*, 2000)

A rational approach was developed by Krasner and Rankow to study the relationships of the pulp chamber to the clinical crown and pulp chamber floor. After several observations, they laid down certain laws which have proven to be valuable aids

to the clinician searching for elusive canals.(Krasner and Rankow, 2004) The clinician should be aware of the fact that in certain cases there is always a possibility of fused or fewer canals although extra canals are more of a rule than an exception.

In a study conducted by Parsiena and Milan, out of the 102 extracted human mandibular second molars, only six teeth (5.88%) were observed with one root having a single root canal. (Mohan et al., 2011) Weine et al conducted a study on 75 extracted mandibular second molars of which only one tooth (1.3%) had a single canal configuration and two teeth (2.7%) were C shaped. These results are in accordance with the observations made in the present study.

Various case reports in literature are an evidence for the rare occurrence of a single fused canal in mandibular second molars.(Roy, 2013; Acharya, 2016; Bansal *et al.*, 2019) Sabala et al has stated that the probability of an aberration is higher if it is rare and hence the clinician should suspect its presence on the contralateral pair.(Sabala, Benenati and Neas, 1994) It has been observed that the occurrence of abnormal anatomy can occur in any racial groups and depends on factors like age, sex and ethnicity. This study reports an association of females with presence of a single fused root and a single canal in mandibular second molars.

The incidence of single canal in maxillary first molar tooth is rare and have been reported by very few authors and the incidence of single canal in maxillary second and third molars is extremely rare.(Fava *et al.*, 2000; Torre *et al.*, 2008) Recently a case report of maxillary first molar with a single root and a single canal was reported by Gopi Krishna et al.(Gopikrishna, Bhargavi and Kandaswamy, 2006). Ioannidis et al reported a case of single root with

single canal in seven teeth if the same patient which included maxillary and mandibular molars. (Ioannidis *et al.*, 2011)However it has been reported in literature that the chance of occurrence of single canals in the mandibular second molar tooth is comparatively higher than their maxillary counterparts.(Skidmore, 1979)

Some of the most common iatrogenic errors in such anomalies occurs when the extra canals are missed.(Cantatore, Berutti and Castellucci, 2006) These can be minimised if the clinician has a thorough knowledge of the general location and dimensions of the pulp chamber as well as the variations and their probability of occurrence along with good preoperative evaluation using radiographs and CBCT. From a clinical perspective, when the initial radiograph shows the image of an unusual anatomic form, it is recommended that a second radiograph is taken with a mesial or distal angulation and also a radiograph of the contralateral tooth. (Fava and Dummer, 1997)

One of the limitations of the present study is that only the radiographs were assessed which allowed a two dimensional analysis only. Furthermore the sample size was small and was restricted to a particular geographic location. Hence, using three dimensional analysis and studying the population over a larger geographical area will allow the results to be generalised to a larger population. Further, bilateral analysis can be conducted to see their association.

IV. CONCLUSION

Under the limitation of present study, out of the 509 mandibular second molars, 8 (1.6%) has the configuration of a single fused root with a single canal. Seven (87.50%) of these eight cases were observed in females and only one(12.50%) was observed in male which is statistically significant.

However from a clinical point of application, a complete examination from multiple angled radiographs and three dimensional assessment must be conducted when an unusual anatomic form is encountered. This will reveal accurate details and will help in preventing iatrogenic errors which often lead to the failure of endodontic treatment.

CONFLICT OF INTEREST: There is no conflict of interest.

AUTHORS CONTRIBUTION: All authors have contributed equally in bringing out this research work.

V. REFERENCES

- [1] Acharya, S. (2016) 'Single canal in a single-rooted mandibular second molar: An enigma', *The Saint's International Dental Journal*, p. 50. doi: 10.4103/2454-3160.202221.
- [2] Bansal, P. *et al.* (2019) 'Maxillary second molar with single root and single canal: A case series', *Endodontology*, p. 129. doi: 10.4103/endo.endo_87_18.
- [3] Cantatore, G., Berutti, E. and Castellucci, A. (2006) 'Missed anatomy: frequency and clinical impact', *Endodontic Topics*, pp. 3–31. doi: 10.1111/j.1601-1546.2009.00240.x.
- [4] Cimilli, H. *et al.* (2005) 'Spiral computed tomographic demonstration of C-shaped canals in mandibular second molars', *Dento maxillo facial radiology*, 34(3), pp. 164–167.
- [5] Cooke, H. G., Groves Cooke, H. and Cox, F. L. (1979) 'C-shaped canal configurations in mandibular molars', *The Journal of the American Dental Association*, pp. 836–839. doi: 10.14219/jada.archive.1979.0402.
- [6] Fan, B., Cheung, G., Fan, M., Gutmann, J. and Bian, Z. (2004) 'C-shaped Canal System in Mandibular Second Molars: Part I—Anatomical Features', *Journal of Endodontics*, pp. 899–903. doi: 10.1097/01.don.0000136207.12204.e4.
- [7] Fan, B., Cheung, G., Fan, M., Gutmann, J. and Fan, W. (2004) 'C-Shaped Canal System in Mandibular Second Molars: Part II—Radiographic Features', *Journal of Endodontics*, pp. 904–908. doi: 10.1097/01.don.0000136206.73115.93.
- [8] Fan, W. *et al.* (2008) 'Identification of a C-shaped Canal System in Mandibular Second Molars—Part III: Anatomic Features Revealed by Digital Subtraction Radiography', *Journal of Endodontics*, pp. 1187–1190. doi: 10.1016/j.joen.2008.06.013.
- [9] Fava, L. R. *et al.* (2000) 'Four second molars with single roots and single canals in the same patient', *International endodontic journal*, 33(2), pp. 138–142.
- [10] Fava, L. R. G. and Dummer, P. M. H. (1997) 'Periapical radiographic techniques during endodontic diagnosis and treatment', *International Endodontic Journal*, pp. 250–261. doi: 10.1111/j.1365-2591.1997.tb00705.x.
- [11] Fernandes, M., de Ataide, I. and Wagle, R. (2014) 'C-shaped root canal configuration: A review of literature', *Journal of Conservative Dentistry*, p. 312. doi: 10.4103/0972-0707.136437.
- [12] Gopikrishna, V., Bhargavi, N. and Kandaswamy, D. (2006) 'Endodontic Management of a Maxillary First Molar with a Single Root and a Single Canal Diagnosed with the Aid of Spiral CT: A Case Report', *Journal of Endodontics*, pp. 687–691. doi: 10.1016/j.joen.2005.10.057.
- [13] Ioannidis, K. *et al.* (2011) 'Endodontic Management and Cone-beam Computed Tomography Evaluation of Seven Maxillary

- and Mandibular Molars with Single Roots and Single Canals in a Patient', *Journal of Endodontics*, pp. 103–109. doi: 10.1016/j.joen.2010.09.001.
- [14] Janani, K., Palanivelu, A. and Sandhya, R. (2020) 'Diagnostic accuracy of dental pulse oximeter with customized sensor holder, thermal test and electric pulp test for the evaluation of pulp vitality - An in vivo study', *Brazilian Dental Science*. doi: 10.14295/bds.2020.v23i1.1805.
- [15] Jose, J., P., A. and Subbaiyan, H. (2020) 'Different Treatment Modalities followed by Dental Practitioners for Ellis Class 2 Fracture – A Questionnaire-based Survey', *The Open Dentistry Journal*, pp. 59–65. doi: 10.2174/1874210602014010059.
- [16] Krasner, P. and Rankow, H. J. (2004) 'Anatomy of the pulp-chamber floor', *Journal of endodontia*, 30(1), pp. 5–16.
- [17] Kumar, D. and Delphine Priscilla Antony, S. (2018) 'Calcified Canal and Negotiation-A Review', *Research Journal of Pharmacy and Technology*, p. 3727. doi: 10.5958/0974-360x.2018.00683.2.
- [18] Malagnino, V., Gallottini, L. and Passariello, P. (1997) 'Some unusual clinical cases on root anatomy of permanent maxillary molars', *Journal of Endodontics*, pp. 127–128. doi: 10.1016/s0099-2399(97)80260-9.
- [19] Manning, S. A. (1990) 'Root canal anatomy of mandibular second molars. Part I', *International Endodontic Journal*, pp. 34–39. doi: 10.1111/j.1365-2591.1990.tb00800.x.
- [20] Manohar, M. P. and Sharma, S. (2018) 'A survey of the knowledge, attitude, and awareness about the principal choice of intracanal medicaments among the general dental practitioners and non endodontic specialists', *Indian journal of dental research: official publication of Indian Society for Dental Research*, 29(6), pp. 716–720.
- [21] Mohan, A.G., Ebenezar, A.R. and Mary, A.V., Molars with Single Root and Single Canals. *The Journal of the Indian A*, 2011(18 SUPPL III), p.1144.
- [22] Nandakumar, M. and Nasim, I. (2018) 'Comparative evaluation of grape seed and cranberry extracts in preventing enamel erosion: An optical emission spectrometric analysis', *Journal of conservative dentistry: JCD*, 21(5), pp. 516–520.
- [23] Nasim, I. *et al.* (2018) 'Clinical performance of resin-modified glass ionomer cement, flowable composite, and polyacid-modified resin composite in noncarious cervical lesions: One-year follow-up', *Journal of Conservative Dentistry*, p. 510. doi: 10.4103/jcd.jcd_51_18.
- [24] Noor, S. S. S. E., S Syed Shihaab and Pradeep (2016) 'Chlorhexidine: Its properties and effects', *Research Journal of Pharmacy and Technology*, p. 1755. doi: 10.5958/0974-360x.2016.00353.x.
- [25] Orban, B. and Mueller, E. (1929) 'The Development of the Bifurcation of Multirooted Teeth', *The Journal of the American Dental Association (1922)*, pp. 297–319. doi: 10.14219/jada.archive.1929.0051.
- [26] Rajendran, R. *et al.* (2019) 'Comparative Evaluation of Remineralizing Potential of a Paste Containing Bioactive Glass and a Topical Cream Containing Casein Phosphopeptide-Amorphous Calcium Phosphate: An in Vitro Study', *Pesquisa Brasileira em Odontopediatria e Clínica Integrada*, pp. 1–10. doi: 10.4034/pboci.2019.191.61.
- [27] Ramamoorthi, S., Nivedhitha, M. S. and Divyanand, M. J. (2015) 'Comparative evaluation of postoperative pain after using endodontic needle and EndoActivator during

- root canal irrigation: A randomised controlled trial’, *Australian endodontic journal: the journal of the Australian Society of Endodontology Inc*, 41(2), pp. 78–87.
- [28] Ramanathan, S. and Solete, P. (2015) ‘Cone-beam Computed Tomography Evaluation of Root Canal Preparation using Various Rotary Instruments: An in vitro Study’, *The Journal of Contemporary Dental Practice*, pp. 869–872. doi: 10.5005/jp-journals-10024-1773.
- [29] Ravinthar, K. and Jayalakshmi (2018) ‘Recent Advancements in Laminates and Veneers in Dentistry’, *Research Journal of Pharmacy and Technology*, p. 785. doi: 10.5958/0974-360x.2018.00148.8.
- [30] Roy, A. (2013) ‘Mandibular Second Molar with a Single Root and a Single Canal: Case Series’, *JOURNAL OF CLINICAL AND DIAGNOSTIC RESEARCH*. doi: 10.7860/jcdr/2013/6172.3635.
- [31] R, R., Rajakeerthi, R. and Ms, N. (2019) ‘Natural Product as the Storage medium for an avulsed tooth – A Systematic Review’, *Cumhuriyet Dental Journal*, pp. 249–256. doi: 10.7126/cumudj.525182.
- [32] Sabala, C. L., Benenati, F. W. and Neas, B. R. (1994) ‘Bilateral root or root canal aberrations in a dental school patient population’, *Journal of endodontia*, 20(1), pp. 38–42.
- [33] Siddique, R. *et al.* (2019) ‘Qualitative and quantitative analysis of precipitate formation following interaction of chlorhexidine with sodium hypochlorite, neem, and tulsi’, *Journal of conservative dentistry: JCD*, 22(1), pp. 40–47.
- [34] Skidmore, A. E. (1979) ‘The importance of preoperative radiographs and the determination of root canal configuration’, *Quintessence international, dental digest*, 10(3), pp. 55–61.
- [35] Teja, K.V. and Ramesh, S., 2019. Shape optimal and clean more. *Saudi Endodontic Journal*, 9(3), p.235.
- [36] Teja, K. V., Ramesh, S. and Priya, V. (2018) ‘Regulation of matrix metalloproteinase-3 gene expression in inflammation: A molecular study’, *Journal of conservative dentistry: JCD*, 21(6), pp. 592–596.
- [37] Torre, F. de la *et al.* (2008) ‘Single-rooted maxillary first molar with a single canal: endodontic retreatment’, *Oral Surgery, Oral Medicine, Oral Pathology, Oral Radiology, and Endodontology*, pp. e66–e68. doi: 10.1016/j.tripleo.2008.07.024.
- [38] Weine, F. S. (1998) ‘The C-shaped mandibular second molar: Incidence and other considerations’, *Journal of Endodontics*, pp. 372–375. doi: 10.1016/s0099-2399(98)80137-4.
- [39] Weine, F. S., Pasiewicz, R. A. and Ted Rice, R. (1988) ‘Canal configuration of the mandibular second molar using a clinically oriented in vitro method’, *Journal of Endodontics*, pp. 207–213. doi: 10.1016/s0099-2399(88)80171-7.
- [40] Zuben, M. von *et al.* (2017) ‘Worldwide Prevalence of Mandibular Second Molar C-Shaped Morphologies Evaluated by Cone-Beam Computed Tomography’, *Journal of Endodontics*, pp. 1442–1447. doi: 10.1016/j.joen.2017.04.016.

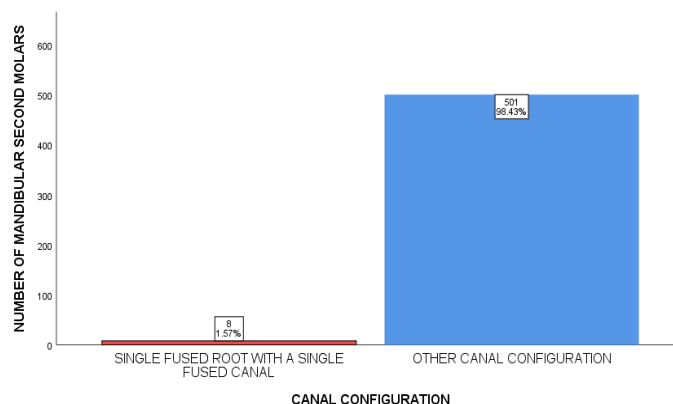


Fig 1: Bar Graph represents the frequency distribution of the occurrence of a single fused canal in mandibular second molars. The X axis represents the type of canal and the Y axis represents the number of mandibular second molars. Out of a total of 509 mandibular second molars, only 8 (1.6%) had a single fused root with a single canal.

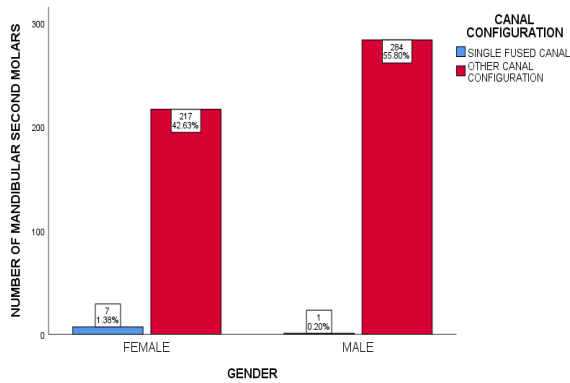


Fig 2: Bar graph represents the association between gender and canal configuration in mandibular second molar. X axis represents the gender and the Y axis represents the number of mandibular second molars. 7 mandibular second molars having a single fused canal were observed in females and 1 in male. Chi square value- 6.239, $p = 0.012 (< 0.05)$. There is a strong association of a single fused canal in mandibular second molars with female gender.