

ASSOCIATION BETWEEN TRAUMA FROM OCCLUSION AND PERIODONTAL STATUS OF MANDIBULAR ANTERIOR TEETH

Haripriya. R¹, Arvina Rajasekar², Nivethigaa. B³

¹Saveetha Dental College and Hospitals, Saveetha Institute of Medical and Technical Sciences, Saveetha University, Chennai, India Mail id: 151701011.sdc@saveetha.com

²Senior Lecturer, Department of Periodontics, Saveetha Dental College and Hospitals, Saveetha Institute of Medical and Technical Sciences, Saveetha University, Chennai, India Mail id: arvinar.sdc@saveetha.com

³Senior Lecturer, Department of Orthodontics, Saveetha Dental College and Hospitals, Saveetha Institute of Medical and Technical Sciences, Saveetha University, Chennai, India Mail id: nivethigaab.sdc@saveetha.com

Article Info

Volume 82

Page Number: 17253 - 17258

Publication Issue:

January - February 2020

Article History

Article Received: 18 October 2019

Revised: 14 November 2019

Accepted: 22 December 2019

Publication: 29 February 2020

Abstract:

Any occlusal force which goes beyond the adaptive capacity of our periodontium causes injury to periodontal structure, and the resultant trauma is called trauma from occlusion (TFO). Several views have been interpreted as trauma from occlusion as an etiological factor or cofactor for occurrence of periodontal status. The aim of the present study was to assess the association between trauma from occlusion and mandibular anterior teeth. This retrospective study was conducted in a private institution in Chennai using the patient records from June 2019 to March 2020. A total of 100 patients were randomly selected and were categorized into two groups; Group 1 (n=50): patients with TFO and Group 2 (n=50): patients without TFO. Data regarding the presence or absence of clinical attachment loss and mobility of mandibular anterior teeth was collected from the record and analysed. Descriptive and inferential statistics were done using SPSS software, Version 23. In the present study, majority of the patients with trauma from occlusion presented with clinical attachment loss (43%) and mobility in mandibular anterior teeth (38%). Also, there was a statistically significant association between trauma from occlusion and periodontal disease in mandibular anterior teeth. (p=0.000)

Keywords: Clinical attachment loss; Mandibular anterior teeth; Mobility; Periodontitis; Trauma from occlusion.

I. INTRODUCTION

A harmonious relationship between occlusion and periodontium is considered essential to maintain a healthy dentition (Harrel and Nunn, 2004). The teeth and periodontium are usually prevented from detrimental forces in centric and eccentric relations. When occlusion is not favourable, this protection mechanism will be

disturbed. Few cusps or single cusp bear the occlusal forces initially during law closure. This affects the periodontal tolerance of teeth which exhibits occlusal interferences (Prasad *et al.*, 2013). Any occlusal force that goes beyond the adaptive capacity of the periodontium can cause injury to the periodontal structure and the resultant trauma is called trauma from occlusion (Singh, Jalaluddin and

Rajeev, 2017). The role of occlusion and its impact on periodontium has been a controversial and debatable issue for many years. Though a variety of occlusal conditions have been related to the periodontal interaction, the main focus is on occlusal trauma resulting from excessive forces exerted on the periodontium (Hallmon and Harrel, 2004; Lindhe, Lang and Karring, 2008).

Gingival recession is the denudation of tooth cementum by an apical shift in the position of gingiva in the root apex direction. When the gingival recession occurs in mandibular anterior teeth, problems imposed with esthetic concern, increased chances of developing hypersensitivity and root caries (Loe *et al.*, 1978). With increasing concern on esthetics, soft tissue framing the dentition is also focused (Thamaraiselvan *et al.*, 2015). The esthetics is maintained by an harmonious relationship between lip, teeth and gingiva (Ramesh *et al.*, 2019). In previous studies it was observed that gingival recession is one of the potential complications of traumatic occlusal forces (Kundapur, Bhat and Bhat, 2009).

Trauma from occlusion that exerts excessive occlusal forces has adverse effects on the tooth supporting structure ('Parameter on occlusal traumatism in patients with chronic periodontitis. American Academy of Periodontology', 2000). The symptoms of trauma from occlusion includes periodontal and pulpal pain, temporomandibular joint pain, masticatory muscle pain, pain during chewing or percussion, fremitus, prematurity or occlusal discrepancies, wear facets, tooth migration, cracked or fractured tooth and thermal sensitivity (Junqueira, De Siqueira F. Anzaloni Saavedra and De Macedo, 2015) (Sanadi *et al.*, 2016). However, trauma from occlusion is not always indicated by increased tooth mobility (Davies *et al.*, 2001)

(Harrel, 2003). Also, TFO can accelerate further attachment loss in patients with active periodontitis (Davies *et al.*, 2001) (Kavarthapu and Thamaraiselvan, 2018) (Khalid *et al.*, 2017) (Ramamurthy and Mg, 2018) (Ramesh, Sheeja Saji Varghese, *et al.*, 2016; Ramesh, Sheeja S. Varghese, *et al.*, 2016; Priyanka *et al.*, 2017) (Varghese *et al.*, 2015) (Panda *et al.*, 2014; Khalid *et al.*, 2016; Mootha *et al.*, 2016; Avinash, Malaippan and Dooraiswamy, 2017; Ramesh, Ravi and Kaarthikeyan, 2017; Ravi *et al.*, 2017).

In this context, the aim of the present study was to determine the association between trauma from occlusion and periodontal status of mandibular anterior teeth.

II. MATERIALS AND METHODS

This retrospective study was conducted in a private institution using the patient records from June 2019 to March 2020. Prior permission to utilise the data for the and analysis was obtained from the Institution Ethics Board with the ethical approval number _____ being: SDC/SIHEC/2020/DIASDATA/0619-0320.

A total of 100 patients were randomly selected and were categorized into two groups; Group 1 (n=50): patients with trauma from occlusion and Group 2 (n=50): patients without trauma from occlusion. Data regarding the presence or absence of clinical attachment loss and mobility of mandibular anterior teeth was collected from the case records and analysed. Descriptive (frequency distribution and percentage) and inferential (chi-square test) statistics were done using SPSS software, Version 23.

III. RESULTS AND DISCUSSION

A total of 100 patients were enrolled in the present study and were categorized into two groups; Group 1 (n=50): patients with trauma from occlusion and Group 2 (n=50): patients without trauma from occlusion.

When clinical attachment loss was assessed, among the 50 patients with trauma from occlusion, clinical attachment loss was observed in 43% of the patients. Whereas, among the 50 patients without trauma from occlusion, clinical attachment loss was observed only in 5% of the patients. Association between trauma from occlusion and clinical attachment loss was assessed by chi square test and was found to be statistically significant with the p value of 0.00 [Figure 1]

When mobility in mandibular anterior teeth was assessed among the patients with trauma from occlusion, mobility was observed in 38% of the patients. Whereas among the 50 patients without trauma from occlusion, mobility was present only in 5% of the patients. Association between trauma from occlusion and mobility in mandibular anterior teeth was assessed by chi square test and was found to be statistically significant with p value of 0.00 [Figure 2]

The present study assessed the periodontal status of mandibular anterior teeth among patients with trauma from occlusion. It was observed that the majority of the patients (43%) with trauma from occlusion presented with clinical attachment loss. Singh, et al, commented that trauma from occlusion affects the connective tissue and causes clinical attachment loss. (Singh, Jalaluddin and Rajeev, 2017) Kundapur et al, reported that gingival recession was prevalent in patients with trauma from occlusion.(Kundapur, Bhat and Bhat, 2009) Ustun et

al. suggested that traumatic occlusion will result in gingival recession. (Ustun *et al.*, 2008). Our finding was in accordance with the previous studies.

In the present study, the majority of the patients (38%) with trauma from occlusion had mobility in mandibular anterior teeth. Nunn, et al, suggested that teeth with occlusal discrepancies had more mobility and poorer prognosis than teeth without occlusal discrepancies. (Nunn and Harrel, 2001) Singh, et al, reported that trauma from occlusion can affect the mobility of teeth. (Singh, Jalaluddin and Rajeev, 2017) Rodier stated that tooth mobility has been diagnosed as one of the common clinical signs of occlusal trauma. (Rodier, 1990)

It was observed that both clinical attachment loss and mobility in mandibular anterior teeth were highly prevalent among patients with trauma from occlusion when compared with patients without trauma from occlusion. However, this finding cannot be generalised because of limited sample size. Therefore, more studies are required among the larger population to assess various factors associated with trauma from occlusion and its effect on periodontal health.

IV. CONCLUSION

Within the limitations of the present study, it can be concluded that the majority of the patients with trauma from occlusion presented with clinical attachment loss (43%) and mobility in mandibular anterior teeth (38%). Also, there was a statistically significant association between trauma from occlusion and periodontal disease in mandibular anterior teeth.

AUTHOR CONTRIBUTIONS

Haripriya.R carried out the retrospective study by collecting data and drafted the manuscript after performing the necessary statistical analysis. Arvina Rajasekar aided in the conception of the topic, participated in the study design, statistical analysis and supervised in preparation of the manuscript. Nivethigaa B had participated in the study design and had coordinated in developing the manuscript. All the authors had equally contributed in developing the manuscript.

CONFLICT OF INTEREST

Nil

V. REFERENCES

- [1] Avinash, K., Malaippan, S. and Dooraiswamy, J. N. (2017) 'Methods of Isolation and Characterization of Stem Cells from Different Regions of Oral Cavity Using Markers: A Systematic Review', *International journal of stem cells*, 10(1), pp. 12–20.
- [2] Davies, S. J. *et al.* (2001) 'Occlusal considerations in periodontics', *British dental journal*, 191(11), pp. 597–604.
- [3] Geiger, A. M. (2001) 'Malocclusion as an etiologic factor in periodontal disease: A retrospective essay', *American Journal of Orthodontics and Dentofacial Orthopedics*, pp. 112–115. doi: 10.1067/mod.2001.114537.
- [4] Hakkarainen, K. (1986) 'Relative Influence of Scaling and Root Planing and Occlusal Adjustment on Sulcular Fluid Flow', *Journal of Periodontology*, pp. 681–684. doi: 10.1902/jop.1986.57.11.681.
- [5] Hallmon, W. W. and Harrel, S. K. (2004) 'Occlusal analysis, diagnosis and management in the practice of periodontics', *Periodontology* 2000, 34, pp. 151–164.
- [6] Harrel, S. K. (2003) 'Occlusal forces as a risk factor for periodontal disease', *Periodontology* 2000, 32, pp. 111–117.
- [7] Harrel, S. K. and Nunn, M. E. (2004) 'The effect of occlusal discrepancies on gingival width', *Journal of periodontology*, 75(1), pp. 98–105.
- [8] Junqueira, R. B., De Siqueira F. Anzaloni Saavedra, G. and De Macedo, N. L. (2015) 'Considerations about the relation between occlusal trauma and periodontal/peri-implant disease', *Brazilian Dental Science*, p. 9. doi: 10.14295/bds.2015.v18i2.1079.
- [9] Kavarthapu, A. and Thamaraiselvan, M. (2018) 'Assessing the variation in course and position of inferior alveolar nerve among south Indian population: A cone beam computed tomographic study', *Indian Journal of Dental Research*, p. 405. doi: 10.4103/ijdr.ijdr_418_17.
- [10] Khalid, W. *et al.* (2016) 'Role of endothelin-1 in periodontal diseases: A structured review', *Indian journal of dental research: official publication of Indian Society for Dental Research*, 27(3), pp. 323–333.
- [11] Khalid, W. *et al.* (2017) 'Comparison of Serum Levels of Endothelin-1 in Chronic Periodontitis Patients Before and After Treatment', *Journal of clinical and diagnostic research: JCDR*, 11(4), pp. ZC78–ZC81.
- [12] Kundapur, P. P., Bhat, K. M. and Bhat, G. S. (2009) 'Association of trauma from occlusion with localized gingival recession in mandibular anterior teeth', *Dental research journal*, 6(2), pp. 71–74.
- [13] Lindhe, J., Lang, N. P. and Karring, T. (2008) *Clinical Periodontology and Implant Dentistry, 2 Volumes*. Wiley-Blackwell.
- [14] Loe, H. *et al.* (1978) 'The natural history of

- periodontal disease in man', *Journal of Periodontal Research*, pp. 550–562. doi: 10.1111/j.1600-0765.1978.tb00209.x.
- [15] Mootha, A. *et al.* (2016) 'The Effect of Periodontitis on Expression of Interleukin-21: A Systematic Review', *International journal of inflammation*, 2016, p. 3507503.
- [16] Nunn, M. E. and Harrel, S. K. (2001) 'The effect of occlusal discrepancies on periodontitis. I. Relationship of initial occlusal discrepancies to initial clinical parameters', *Journal of periodontology*, 72(4), pp. 485–494.
- [17] Panda, S. *et al.* (2014) 'Platelet rich fibrin and xenograft in treatment of intrabony defect', *Contemporary clinical dentistry*, 5(4), pp. 550–554.
- [18] 'Parameter on occlusal traumatism in patients with chronic periodontitis. American Academy of Periodontology' (2000) *Journal of periodontology*, 71(5 Suppl), pp. 873–875.
- [19] Prasad, D. K. *et al.* (2013) 'The Influence of Occlusal Trauma on Gingival Recession and Gingival Clefts', *The Journal of Indian Prosthodontic Society*, pp. 7–12. doi: 10.1007/s13191-012-0158-1.
- [20] Priyanka, S. *et al.* (2017) 'Detection of cytomegalovirus, Epstein-Barr virus, and Torque Teno virus in subgingival and atheromatous plaques of cardiac patients with chronic periodontitis', *Journal of Indian Society of Periodontology*, 21(6), pp. 456–460.
- [21] Ramamurthy, J. and Mg, V. (2018) 'Comparison of effect of hiora mouthwash versus chlorhexidine mouthwash in gingivitis patients: A clinical trial', *Asian Journal of Pharmaceutical and Clinical Research*, p. 84. doi: 10.22159/ajpcr.2018.v11i7.24783.
- [22] Ramesh, A., Varghese, S. S., *et al.* (2016) 'Chronic obstructive pulmonary disease and periodontitis – unwinding their linking mechanisms', *Journal of Oral Biosciences*, pp. 23–26. doi: 10.1016/j.job.2015.09.001.
- [23] Ramesh, A., Varghese, S. S., *et al.* (2016) 'Herbs as an antioxidant arsenal for periodontal diseases', *Journal of intercultural ethnopharmacology*, 5(1), pp. 92–96.
- [24] Ramesh, A. *et al.* (2019) 'Esthetic lip repositioning: A cosmetic approach for correction of gummy smile - A case series', *Journal of Indian Society of Periodontology*, 23(3), pp. 290–294.
- [25] Ramesh, A., Ravi, S. and Kaarthikeyan, G. (2017) 'Comprehensive rehabilitation using dental implants in generalized aggressive periodontitis', *Journal of Indian Society of Periodontology*, p. 160. doi: 10.4103/jisp.jisp_213_17.
- [26] Ramfjord, S. P. and Ash, M. M., Jr (1981) 'Significance of occlusion in the etiology and treatment of early, moderate, and advanced periodontitis', *Journal of periodontology*, 52(9), pp. 511–517.
- [27] Ravi, S. *et al.* (2017) 'Additive Effect of Plasma Rich in Growth Factors With Guided Tissue Regeneration in Treatment of Intrabony Defects in Patients With Chronic Periodontitis: A Split-Mouth Randomized Controlled Clinical Trial', *Journal of Periodontology*, pp. 839–845. doi: 10.1902/jop.2017.160824.
- [28] Rodier, P. (1990) '[Clinical research on the etiopathology of gingival recession]', *Journal de parodontologie*, 9(3), pp. 227–234.
- [29] Sanadi, D. R. M. *et al.* (2016) 'Role of trauma from occlusion in periodontal disease- A controversy', *IOSR Journal of Dental and Medical Sciences*, pp. 118–122. doi: 10.9790/0853-150904118122.
- [30] Singh, D., Jalaluddin, M. and Rajeev, R. (2017) 'Trauma from occlusion: The overstrain of the supporting structures of the teeth', *Indian*

Journal of Dental Sciences, p. 126. doi: 10.4103/ijds.ijds_21_16.

- [31] Slots, J. and Rams, T. E. (1990) ‘Antibiotics in periodontal therapy: advantages and disadvantages’, *Journal of Clinical Periodontology*, pp. 479–493. doi: 10.1111/j.1365-2710.1992.tb01220.x.
- [32] Thamaraiselvan, M. *et al.* (2015) ‘Comparative clinical evaluation of coronally advanced flap with or without platelet rich fibrin membrane in the treatment of isolated gingival recession’, *Journal of Indian Society of Periodontology*, 19(1), pp. 66–71.
- [33] Ustun, K. *et al.* (2008) ‘Severe gingival recession caused by traumatic occlusion and mucogingival stress: a case report’, *European journal of dentistry*, 2(2), pp. 127–133.
- [34] Varghese, S. S. *et al.* (2015) ‘Estimation of salivary tumor necrosis factor-alpha in chronic and aggressive periodontitis patients’, *Contemporary clinical dentistry*, 6(Suppl 1), pp. S152–6.

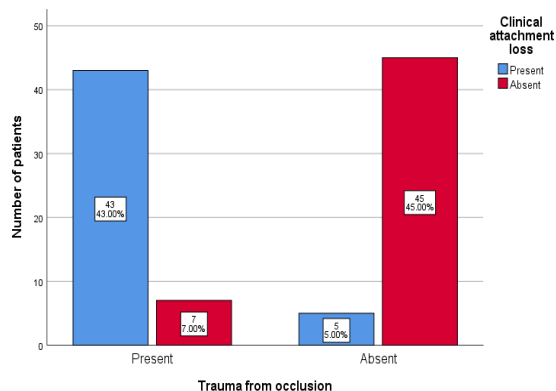


Figure 1: Bar graph showing the association between trauma from occlusion and clinical attachment loss. X axis represents the presence or absence of trauma from occlusion and Y axis represents the number of patients with clinical attachment loss. Majority of the patients (43%) with trauma from occlusion had clinical attachment loss. Association between trauma from occlusion and

clinical attachment loss was statistically significant. (Chi-square test; $p=0.00$)

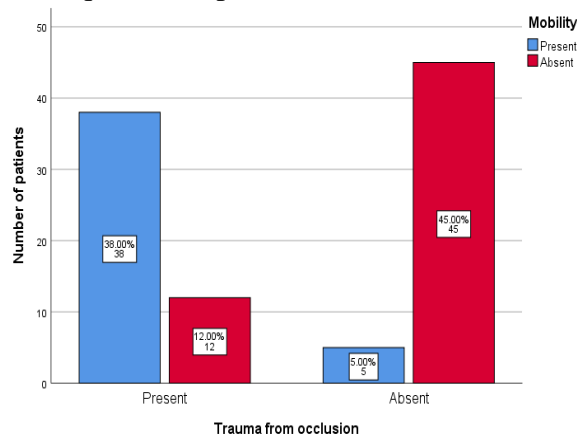


Figure 2: Bar graph showing the association between trauma from occlusion and mobility. X axis represents the presence or absence of trauma from occlusion and Y axis represents the number of patients with mobility. Majority of the patients (38%) with trauma from occlusion had mobility. Association between trauma from occlusion and mobility was statistically significant. (Chi-square test; $p=0.00$)