

RETROSPECTIVE ANALYSIS ON SUTURES USED FOR OPEN METHOD EXTRACTION IN PATIENTS ATTENDING A PRIVATE DENTAL INSTITUTION

Kausalyah Krisna Malay¹, Balakrishnan R.N², Jayanth Kumar.V³

¹Saveetha Dental College And Hospitals, Saveetha Institute Of Medical And Technical Sciences, Saveetha University Chennai, India
Email: 151301085.sdc@saveetha.com Contact Number:+91 9003182632

²Senior Lecturer, Department of Oral Surgery, Saveetha Dental College And Hospitals, Saveetha Institute Of Medical And Technical Sciences, Saveetha University Chennai, India Email: balakrishnarn.sdc@saveetha.com

³Reader, Department of Oral Medicine, Saveetha Dental College And Hospitals, Saveetha Institute Of Medical And Technical Sciences, Saveetha University Chennai, India Email: jayanthkumar@saveetha.com

Article Info

Volume 82

Page Number: 17174 - 17181

Publication Issue:

January - February 2020

Article History

Article Received: 18 October 2019

Revised: 14 November 2019

Accepted: 22 December 2019

Publication: 29 February 2020

Abstract:

Procedure for open method extraction, initially starts with giving local anaesthesia injection and followed by incisions and flap design. Sutures are defined as stitches or series of stitches made to secure apposition of the edges of a surgical or traumatic wound. It is also defined as any strand or material utilized to ligate blood vessels or approximate tissues. To determine the presences of sutures in open method extraction The purpose of the study was to assess the sutures in open method extraction (post operatively). A study was carried out by collecting data by reviewing patients data and analysing the data of 86000 patients between June 2019 and March 2020 at the private dental institute. The sample size that was taken is 292 patients who came to the private dental institute for consultation. The case sheets of those patients were reviewed for presence or absence of sutures post operative to open method extraction. Data was statistically analysed using SPSS 2.0, Chi-Square Test was conducted. Result was recorded. Majority of the dental students used suturing as the wound closure for post operative open method extraction procedure. Within the limitation of the study, male patients were predominant and suture was present in majority cases of post open method extraction. And the most common site which underwent open method extraction was tooth number 48 and 38 (lower third molars).

Keywords: extraction; open method; suture; transalveolar.

I. INTRODUCTION

Open method extraction also known as transalveolar extraction.(Jesudasan, Wahab and Sekhar, 2015) This method involves the reflection of a muco - periosteal flap, cutting of bone obstructing the removal of the tooth and if required, sectioning of the roots and then removal.(Nageshwar, 2002) Exodontia is also defined as painless removal of the

whole of the tooth or part of the tooth with minimal trauma to investing tissues so that the wound heals uneventfully and no part - operative prosthetic problem is created.(Coulthard et al., 2014) (Mp and Rahman, 2017) There are two types of exodontia are intra - oral extraction also known as forceps extraction. Closed method technique of extraction

with the use of forcep and elevators.(Christabel et al., 2016)

Another extra - alveolar extraction commonly called as surgical extraction or transalveolar extraction. It is also known as open view technique.(Barone et al., 2010) Indications for transalveolar extraction are any tooth which offers a lot of resistance in forcep extraction.(Marimuthu et al., 2018) Moreover, retained roots which cannot be grasped by the root forceps and also in cases of hypercementosis of a tooth. The radiographic evidence of complicated or difficult root patterns. The sclerosis of bone. In addition, cases with teeth associated with pathology and impacted teeth and embedded teeth.(Chukwunke, Oji and Saheeb, 2008)

Contraindications for open extraction severe and uncontrolled diabetes. Infected extraction sites are not eligible for this type of open extraction.(Packiri, Gurunathan and Selvarasu, 2017) Patients with hypertension and asthma or other respiratory problems are contraindicated. Also, patients with pregnancy of the first and third trimester. In hemophilia patients and immuno - compromised patients, open method extraction will not be performed.(Danda et al., 2010) However, there are so many advantages in open method extractions such as giving good visibility, easy access, prevents laceration of gingiva, prevents traumatization of bone and fracture of tooth, reduces postoperative complications.(Mp, 2017) (Maria, Malik and Virang, 2012)

Procedure for open method extraction, initially starts with giving local anaesthesia injection and followed by incisions and flap design.(Patil et al., 2017) After that, bone will be removed for teeth sectioning, next, elevation of the involved tooth will be done. Smoothing of sharp edges of bone with

debridement of socket. Finally, suturing of the flap will be proceeded. Sutures are defined as stitches or series of stitches made to secure apposition of the edges of a surgical or traumatic wound. It is also defined as any strand or material utilized to ligate blood vessels or approximate tissues.(Rao and M.P. Santhosh kumar M.D.S, 2018)

Usually, sutures are given to provide an adequate tension of wound closure without dead space but loose enough to obviate tissue ischemia and necrosis. An ideal suture should be highly not security, highly breaking strength. It also should be a minimal tissue reaction to enhance the healing process.(Abhinav et al., 2019) In case of open method extraction, usually simple interrupted suture or continuous sutures are given. The most commonly used suturing techniques in oral cavity are simple interrupted suture and simple continuous suture, also vertical and horizontal mattress sutures.(Jain, Muthusekhar and Baig, 2019)

Simple interrupted suture is the most commonly used. Inserted singly through the side of the wound and tied with a surgeon's knot. There are many advantages such as its strong properties and can be used in areas of stress. Moreover, it is placed 4-8mm apart to close large wounds so that tension is shared. In addition, the degree of eversion produced in this technique. Additionally, free of interference between each stitch and easy access to clean.(Santhosh Kumar and Sneha, 2016)

A simple interrupted suture placed and needle re inserted in a continuous fashion such that the suture passes perpendicular to the incision line below and obliquely above. Ended by passing a knot over the untightened and of the suture. Advantages of his technique are rapid technique and distributes tension uniformly. It is also more water tight closure and only two knots with associated tags.(Kumar, 2017)

Finally, suture removal depends on the location and the degree of tension the wound was closed under. (Rahman and Santhoshkumar, 2017) This varies between surgeon and situation, but as a general rule, sutures on the gums and oral cavity are usually removed between ten and fourteen days, post operatively. (Sweta, Abhinav and Ramesh, 2019) The sutures are known to be an important protocol post operative of open method extractions. In some cases, it is evident that no sutures are provided in some open method extractions.

Sutureless techniques such as tissues adhesives, N-Butyl cyanoacrylate adhesive are being used in so many dental practices. However, suturing methods are known to be the traditionally conventional method. (Patturaja and Pradeep, 2016) Therefore, this study was aimed to determine the presence or absence of suture post operative to open method extraction in the private dental institute.

II. METHODS AND MATERIALS

This retrospective study was conducted under a hospital based university setting. Ethical approval for this study was granted by the institute's ethical committee (ethical approval number: SDC/SIHEC/2020/DIASDATA/0619-0320).

Consent to use treatment records for research purposes were obtained from patient/ guardian at the time of patient entry into the university for dental needs. The retrospective data were collected by obtaining and analysing the 89000 dental case records of the university from June 2019 to March 2020. The inclusion criteria for the current study were that patients underwent open method extraction, individuals aged above 17 years old, complete photographic and written records regarding the complete intra-oral examination of the patient. The exclusion criteria were incomplete and censored

dental records, absence of photographic evidence and individuals below the age of 17 years old were excluded.

Presence of sutures were analysed for each of the patients from the sample size. The selected sample sizes were examined by three people; one reviewer, one guide and one researcher. The patients' case sheets were reviewed thoroughly. Cross checking of data including digital entry and intra oral photographs was done by an additional reviewer and as a measure to minimise sampling bias, samples were picked by simple random sampling. Digital entry of clinical examinations and intra oral photographs of selected subjects were assessed and this included the assessment of dental sutures as mentioned before by the examiner based on intraoral photographs and clinical examination data for each of the patients. Those collected data was entered into Microsoft Excel software. The mentioned data were coded and transferred into SPSS PC version 2.0 (IBM 2019) software for statistical analysis. A comparison test, Chi-Square Test was done between the presence and absence of suture placed by the dental students post operatively to open method extraction. The results were recorded. The difference was considered statistically significant as p value was less than 0.05 ($p < 0.05$).

III. RESULTS AND DISCUSSION

Figure 1 showed the gender distribution of patients undergoing open method extraction. The graph showed male patients, 161 patients which is predominant. Whereas, female patients were only 131 patients (44.9%). Male patients were more than half of the total number of patients (55.1%). The most number of teeth that underwent open method extraction was lower molars (78.77%), as shown in Figure 2. The second most tooth which underwent open method extraction was upper molars, with a

frequency of 44 patients (15.07%). Figure 3 showed the frequency of patients who had sutures post operative of open method extraction. Chart showed that the frequency of patients having sutures were 261 patients (89.4%) whereas without sutures were 31 patients only (10.6%).

Figure 4 showed association of teeth involved in open method extraction and evidence of sutures in postoperative to open method extraction. The highest number of sutures present in relation to lower molars . There were 230 patients who underwent open method extractions in relation to these teeth, 207 of them had suture and 23 of them were sutureless after open method extraction was done. This association showed a difference which was statistically significant. (Chi Square Test; $p=0.032$ -significant). The statistical result showed that p value was 0.032. Therefore, the difference is significant as the p value is less than 0.05. Statistical analysis using SPSS 20 for Windows was done and found to be significant.(Pearson Chi Square Value=35.756; $df=22$; $p=0.032$ (<0.05)-significant).

In a similar study conducted by Alsamman et al(Al-Samman, 2016), it showed that there were no significant differences on the outcome between suture and sutureless wound closure. However, in present study the statistic showed a significant difference between both the methods. Eventually, it showed in the present study majority of the dental students had given sutures post operative to post open method extractions. In another similar study, by Osunde et al(Osunde, Adebola and Saheeb, 2012), majority of the participants gave the suture for wound closure and concluded that sutureless although they are simple, cost efficient and time saving but not as accurate as magnetic for measuring facial soft issues. Primary closure of the flap avoids suture dehiscence improves wound healing.

In contrast to previous literature mentioned, Pasqualini et al(Pasqualini et al., 2005) concluded that suture methods were conventionally accepted by majority of dentists as dehiscence of wound occurred within the first one week post operatively, more frequently in sockets with total closure. Waite et al(Waite and Cherala, 2006), described that most dentists give sutureless techniques because they dont require additional hospital visits for suture removal. Most of the previous studies were contradictory to present study as the development of the dentistry era. Most of the operators are reasonably following the recent developments.

As an explanation for the result in present study, operator skills were questionable. The limited material availability in the private institute might be the major reason for this result. Moreover, the limitations of this study were limited sample size, geographic limitation, unicentric study and only one specific wthnic group was involved in this study. In future scope, clinical assessment on baseline of sutures and sutureless method in open method extraction should be provided for the dental students. In future study, larger sample size with multicentered and multiple ethnic groups should be involved to get reasonable and relevant results. The student also needs to improve their knowledge and skills in order to have few options in wound closure methods.

IV. CONCLUSIONS

Within the limitation of the study, a higher number of the dental students provided suture as wound closure post operative to open method extractions compared to sutureless wound closure. The majority of open method extraction was done in relation to the tooth number 38 and 48 (lower third molars).

AUTHOR CONTRIBUTIONS

- Design - Kausalyah Krisna Malay, Balakrishnan
- Intellectual content - Balakrishnan
- Data collection - Kausalyah Krisna Malay
- Data analysis - Balakrishnan, Jayanth Kumar
- Manuscript writing - Kausalyah Krisna Malay
- Manuscript editing - Balakrishnan, Jayanth Kumar

CONFLICT OF INTEREST

The authors declare that there were no conflict of interest

V. REFERENCES

- [1] Abhinav, R. P. et al. (2019) 'The Patterns and Etiology of Maxillofacial Trauma in South India', *Annals of maxillofacial surgery*, 9(1), pp. 114–117.
- [2] Al-Samman, A. A. (2016) 'A Review of Wound Closure Technique-Patient Morbidity Relationship After Wisdom Tooth Surgery', *Iraqi Dental Journal*. [iraqidentaljournal.com](http://www.iraqidentaljournal.com). Available at: <http://www.iraqidentaljournal.com/index.php/irajournal/article/view/101>.
- [3] Barone, A. et al. (2010) 'A randomized clinical evaluation of ultrasound bone surgery versus traditional rotary instruments in lower third molar extraction', *Journal of oral and maxillofacial surgery: official journal of the American Association of Oral and Maxillofacial Surgeons*, 68(2), pp. 330–336.
- [4] Christabel, A. et al. (2016) 'Comparison of pterygomaxillary dysjunction with tuberosity separation in isolated Le Fort I osteotomies: a prospective, multi-centre, triple-blind, randomized controlled trial', *International journal of oral and maxillofacial surgery*, 45(2), pp. 180–185.
- [5] Chukwunke, F. N., Oji, C. and Saheeb, D. B. (2008) 'A comparative study of the effect of using a rubber drain on postoperative discomfort following lower third molar surgery', *International Journal of Oral and Maxillofacial Surgery*, pp. 341–344. doi: 10.1016/j.ijom.2007.11.016.
- [6] Coulthard, P. et al. (2014) 'Surgical techniques for the removal of mandibular wisdom teeth', *Cochrane Database of Systematic Reviews*. doi: 10.1002/14651858.cd004345.pub2.
- [7] Danda, A. K. et al. (2010) 'Influence of Primary and Secondary Closure of Surgical Wound After Impacted Mandibular Third Molar Removal on Postoperative Pain and Swelling—A Comparative and Split Mouth Study', *Journal of Oral and Maxillofacial Surgery*, pp. 309–312. doi: 10.1016/j.joms.2009.04.060.
- [8] Jain, S. V., Muthusekhar, M. R. and Baig, M. F. (2019) 'Evaluation of three-dimensional changes in pharyngeal airway following isolated lefort one osteotomy for the correction of vertical maxillary excess: a prospective ...', *Journal of maxillofacial*. Springer. Available at: <https://link.springer.com/article/10.1007/s12663-018-1113-4>.
- [9] Jesudasan, J. S., Wahab, P. U. A. and Sekhar, M. R. M. (2015) 'Effectiveness of 0.2% chlorhexidine gel and a eugenol-based paste on postoperative alveolar osteitis in patients having third molars extracted: a randomised controlled clinical trial', *The British journal of oral & maxillofacial surgery*, 53(9), pp. 826–830.
- [10] Kumar, S. (2017) 'THE EMERGING ROLE OF BOTULINUM TOXIN IN THE TREATMENT OF OROFACIAL DISORDERS: LITERATURE UPDATE', *Asian Journal of Pharmaceutical and Clinical Research*, p. 21. doi:

- 10.22159/ajpcr.2017.v10i9.16914.
- [11] Maria, A., Malik, M. and Virang, P. (2012) 'Comparison of primary and secondary closure of the surgical wound after removal of impacted mandibular third molars', *Journal of maxillofacial and oral surgery*, 11(3), pp. 276–283.
- [12] Marimuthu, M. et al. (2018) 'Canonical Wnt pathway gene expression and their clinical correlation in oral squamous cell carcinoma', *Indian journal of dental research: official publication of Indian Society for Dental Research*, 29(3), pp. 291–297.
- [13] Mp, S. K. (2017) 'Relationship between dental anxiety and pain experience during dental extractions', *Asian J Pharm Clin Res.* [pdfs.semanticscholar.org](https://pdfs.semanticscholar.org/f024/7b95077e4a0bb861eb9b8b815893f19758d6.pdf). Available at: <https://pdfs.semanticscholar.org/f024/7b95077e4a0bb861eb9b8b815893f19758d6.pdf>.
- [14] Mp, S. K. and Rahman, R. (2017) 'Knowledge, awareness, and practices regarding biomedical waste management among undergraduate dental students', *Asian J Pharm Clin Res.* innovareacademics.org. Available at: <https://innovareacademics.org/journals/index.php/ajpcr/article/download/19101/12066>.
- [15] Nageshwar (2002) 'Comma incision for impacted mandibular third molars', *Journal of oral and maxillofacial surgery: official journal of the American Association of Oral and Maxillofacial Surgeons*, 60(12), pp. 1506–1509.
- [16] Osunde, O. D., Adebola, R. A. and Saheeb, B. D. (2012) 'A comparative study of the effect of suture-less and multiple suture techniques on inflammatory complications following third molar surgery', *International journal of oral and maxillofacial surgery*, 41(10), pp. 1275–1279.
- [17] Packiri, S., Gurunathan, D. and Selvarasu, K. (2017) 'Management of Paediatric Oral Ranula: A Systematic Review', *Journal of clinical and diagnostic research: JCDR*, 11(9), pp. ZE06–ZE09.
- [18] Pasqualini, D. et al. (2005) 'Primary and secondary closure of the surgical wound after removal of impacted mandibular third molars: a comparative study', *International journal of oral and maxillofacial surgery*, 34(1), pp. 52–57.
- [19] Patil, S. B. et al. (2017) 'Comparison of Extended Nasolabial Flap Versus Buccal Fat Pad Graft in the Surgical Management of Oral Submucous Fibrosis: A Prospective Pilot Study', *Journal of maxillofacial and oral surgery*, 16(3), pp. 312–321.
- [20] Patturaja, K. and Pradeep, D. (2016) 'Awareness of Basic Dental Procedure among General Population', *Journal of pharmacy research.* [indianjournals.com](http://www.indianjournals.com). Available at: <http://www.indianjournals.com/ijor.aspx?target=ijor:rjpt&volume=9&issue=9&article=010>.
- [21] Rahman, R. and Santhoshkumar, M. (2017) 'KNOWLEDGE, ATTITUDE, AND AWARENESS OF DENTAL UNDERGRADUATE STUDENTS REGARDING HUMAN IMMUNODEFICIENCY VIRUS/ACQUIRED IMMUNODEFICIENCY SYNDROME PATIENTS'. Available at: <https://www.semanticscholar.org/paper/3909fac48ced958dae41d99dca00d81097480262> (Accessed: 5 June 2020).
- [22] Rao, T. D. and M.P. Santhosh kumar M.D.S (2018) 'Analgesic Efficacy of Paracetamol Vs Ketorolac after Dental Extractions', *Research Journal of Pharmacy and Technology. Research Journal of Pharmacy and Technology*, 11(8), pp. 3375–3379.

- [23] Santhosh Kumar, M. P. and Sneha, S. (2016) 'Knowledge and awareness regarding antibiotics prophylaxis form for infective endocarditis among under graduate dental students', Asian J Pharm Clin Res.
- [24] Sweta, V. R., Abhinav, R. P. and Ramesh, A. (2019) 'Role of Virtual Reality in Pain Perception of Patients Following the Administration of Local Anesthesia', Annals of maxillofacial surgery, 9(1), pp. 110–113.
- [25] Waite, P. D. and Cherala, S. (2006) 'Surgical outcomes for suture-less surgery in 366 impacted third molar patients', Journal of oral and maxillofacial surgery: official journal of the American Association of Oral and Maxillofacial Surgeons, 64(4), pp. 669–673.

GRAPHS

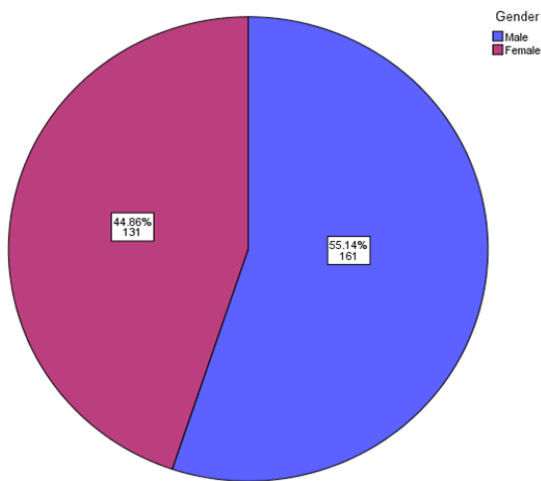


FIGURE 1 - The pie chart represents the distribution of study subjects based on gender, in patients undergoing open method extractions. It was noticed that male patients (violet) were predominant (55.14%) compared to female patients (pink) (44.86%) who underwent open method extractions.

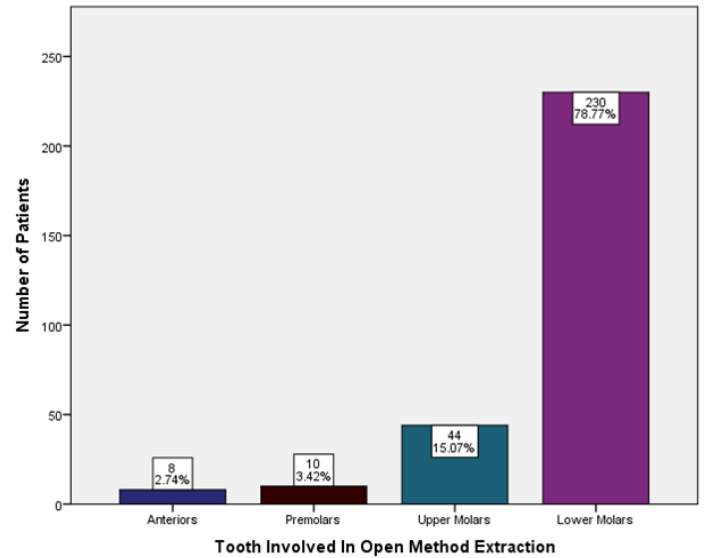


FIGURE 2: The bar graph portrays the tooth involved within the study subjects. X-axis denotes the tooth that is involved in open method extractions and Y-axis denotes the number of patients underwent open method extraction. The graph explains that the highest number of extraction procedures using open method technique was done in lower molars (78.77%).

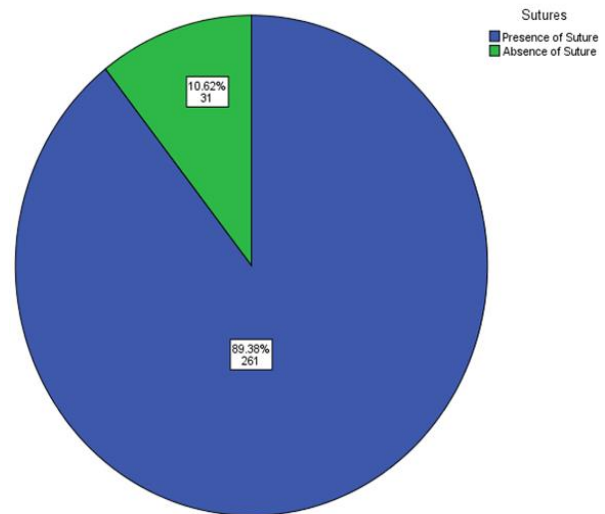


FIGURE 3: The pie chart shows the number and percentage of cases had sutures postoperative to open method extraction. It is noticed that sutures were present (blue) in the majority (89.38%) of cases. Whereas, absence of sutures (green) postoperative to

open method extraction were seen in a minimal number of cases only (10.62%).

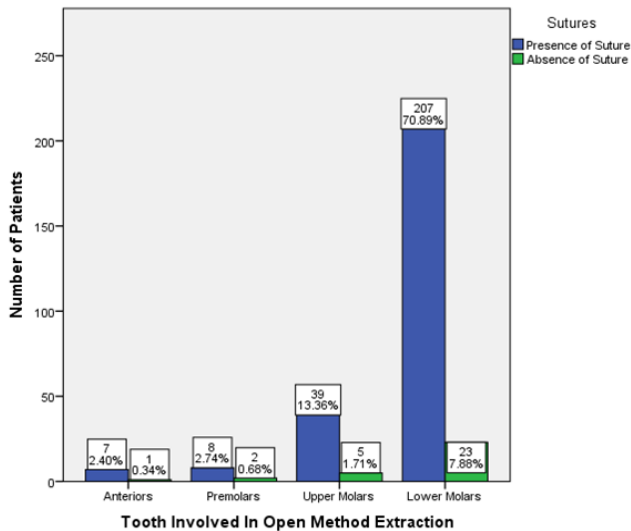


FIGURE 4: The bar graph represents the association between the presence of suture and tooth number. X-axis represents the tooth involved in open method extraction and Y-axis represents the number of patients. The highest number of sutures present (blue) was in lower molars (70.89%). Statistically, the differences were known to be significant. (Pearson Chi Square Value=35.756; df=22; p=0.032 (<0.05)-significant). Implying there are associations between tooth involved and evidence of sutures in open method extractions.