

Assessment of Vertical Bone Loss Sites in Diabetic Patients with Chronic Periodontitis - A Retrospective Study

RUNNING TITLE: Vertical bone loss among diabetic patients with chronic periodontitis

Aparna.M

Saveetha Dental College and Hospitals, Saveetha Institute of Medical and Technical Sciences,
Saveetha University, Chennai, India. Mail Id: 151501019.sdc@saveetha.com

Balaji Ganesh.S*

Senior Lecturer, Department of Periodontics, Saveetha Dental College and Hospitals, Saveetha Institute of Medical and Technical Sciences, Saveetha University, Chennai, India. Email: balajiganeshs.sdc@saveetha.com

Rakshagan V

Senior Lecturer, Department of Prosthodontics, Saveetha Dental College and Hospitals, Saveetha Institute of Medical and Technical Science, Saveetha University, Chennai, India. Mail Id: rakshagan.sdc@saveetha.com

Article Info

Volume 83

Page Number: 2618 - 2624

Publication Issue:

July-August 2020

Article History

Article Received: 06 June 2020

Revised: 29 June 2020

Accepted: 14 July 2020

Publication: 25 July 2020

Abstract

Periodontitis is known as the sixth complication of diabetes mellitus. Alveolar bone loss is one of the major outcomes of periodontitis and diabetes is considered to be the primary risk factors for periodontal disease. Patients with diabetes mellitus have a greater chance of developing destructive periodontal disease as well as greater chance of experiencing progressive alveolar bone loss. The aim of this study is to assess the vertical bone loss sites among diabetic patients with chronic periodontitis. In this study sample size is selected according to inclusion criteria, among patients with both periodontitis and diabetes. Among 10,000 case records evaluated, a total of two hundred diabetic patients had periodontitis who were taken into the study. Vertical bone loss among each patient was assessed from the data retrieved from the dental records of Saveetha Dental College, Chennai. Overall, vertical bone loss was more common in maxillary posteriors than other teeth among diabetic patients with chronic periodontitis. It was commonly seen among males and was profoundly found in the age group of 30 to 50 years. The association between age and gender distribution with vertical bone loss sites was found to be statistically significant.

Keywords: Diabetes mellitus, Periodontitis, Regeneration, Vertical bone loss.

INTRODUCTION

Periodontal disease is induced by bacterial plaque that stimulates a host response in the adjacent gingiva that

leads to the destruction of connective tissue and bone. Plaque accumulation allows the growth of anaerobic bacteria, which eventually leads to the recruitment and

activation of neutrophils. This further results in the upregulation of pro-inflammatory cytokines and also leads to the release of neutrophilic enzymes and ROS. Clinical manifestations of periodontitis include periodontal pocket, gingival swelling, pain, tooth mobility, furcation involvement, attachment loss and severe bleeding on probing (Ramesh, Sheeja Saji Varghese, *et al.*, 2016). The progression of periodontal disease may be affected by certain systemic conditions in which diabetes is considered to be most commonly involved in periodontal disease.

Diabetes mellitus is a heterogeneous group of disorders and it is characterized by high blood glucose levels. (Bell and Polonsky, 2001), (Zimmet, Alberti and Shaw, 2001). Diabetes mellitus can have adverse effects on periodontal disease as it causes production of higher levels of pro-inflammatory cytokines, such as IL-1 and TNF- α , leading to greater bone loss (Kaul *et al.*, 2012). TNF- α has a myriad of actions, mostly pro-inflammatory. Leukocyte recruitment and vascular permeability are facilitated by the stimulated expression of selectins and adhesins by TNF- α . Macrophage induced angiogenesis is also mediated by TNF- α and has a pivotal role in vascular proliferation in the periodontal granulation tissue formation. In response to bacterial LPS, TNF- α triggers osteoclast activation, proliferation and differentiation resulting in bone resorption (Varghese *et al.*, 2015).

Alveolar bone is a part of the cortical bone that forms and supports the tooth socket. Radiographic representation of a normal alveolar bone is a thin layer of radiopaque cortical bone around the teeth. Bone loss that occurs in periodontitis disease has a pattern of vertical and horizontal (Association and American Diabetes Association, 2005). Horizontal bone damage pattern involves a decrease in alveolar peak height with the bone margins that remain perpendicular to the tooth surface. Whereas, in a vertical bone loss pattern angular

bone defects which occur in an oblique direction (Bacić, Plancak and Granić, 1988), (Campus *et al.*, 2005). Bone loss is considered vertical (angular) when the crest of the proximal bone is not parallel to the imaginary line drawn between the CEJ of adjacent teeth.

Vertical bone loss is usually localized and related to factors such as trauma from occlusion, calculus, subgingival plaque, overhanging restorations, and food impaction. It is associated with the intrabony pocket formation. Vertical defects are broadly classified as one wall, two wall, and three wall defects. A vertical defect that involves more than one surface of the tooth is referred to as circumferential defect. Attempts to regenerate lost alveolar bone have been elusive and such a goal is always the dream of both the periodontists and the patients. Such regenerative attempts are at great expense, and even then, the results are not unequivocal. If such is the case of angular bone loss with well-entrenched trough-like defects only being eligible for regenerative procedure. Therefore it is important to identify vertical bone loss at an earlier stage of progression and to treat it (Nainggolan and Gunasagaran, 2018). Patients with diabetes mellitus have a greater chance of developing destructive periodontal disease as well as greater chance of experiencing progressive alveolar bone loss (Ryan *et al.*, 1999), (Mealey and Ocampo, 2007). Therefore, the main aim of this study is to assess the vertical bone loss sites in diabetic patients with chronic periodontitis.

MATERIALS AND METHODS

Study design

A retrospective study was conducted in private dental college, Chennai. A total of two hundred patients with chronic periodontitis who sustain diabetes mellitus were taken into the study.

Ethicals

Before scheduling the retrospective study, the official permission was obtained from the Institutional ethical committee (ethical approval number - SDC/SIHEC/2020/DIASDATA/0619-0320).

Data collection

Among 10,000 case records evaluated, a total of two hundred patients with chronic periodontitis who sustain diabetes mellitus were taken into the study. Vertical bone loss among each patient was assessed from the intraoral periapical radiographs data retrieved from the dental records of Private Dental College, Chennai. Data collection includes various parameters such as age (30 to 80 years), gender (male or female), vertical bone loss patterns in diabetic patients with periodontitis among maxilla and mandibular regions which was assessed by radiographic examination. These data were retrieved from dental records between the time period of June 2019 to March 2020. Incomplete case records were excluded from the study.

Inclusion and exclusion criteria

Inclusion criteria involved both males and females who are diabetic and also had chronic periodontitis. Age range was 30 to 80 years. Dental records about their vertical bone loss patterns were assessed. Whereas, exclusion criteria includes patients who had previously undergone periodontal treatment.

Statistical analysis

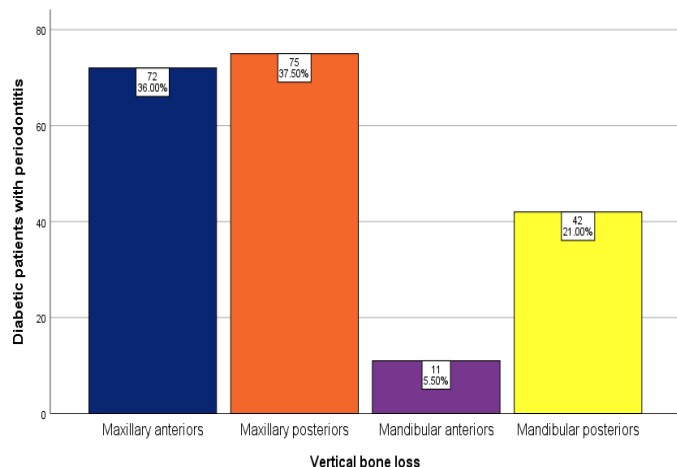
The Data collected was tabulated in excel sheets and were imported to SPSS (version 26.0). Data was analysed using chi-square test and frequency of distribution of the disease which was used to determine the vertical bone loss in diabetic patients with chronic periodontitis among the selected population. The level for a statistical significance was set at $p < 0.05$. The results were demonstrated in the form of bar graphs.

RESULTS AND DISCUSSION

Progression of bone loss in diabetic patients with periodontitis is mainly due to changes in blood vessels, impaired neutrophil function, collagen synthesis, microbiological factors and genetic predisposition. Diabetes mellitus and periodontal disease are more common worldwide (Nainggolan and Gunasagaran, 2018). It can increase the severity of periodontitis and have a significant impact on overall health, controlling blood sugar and various other factors. Therefore periodontal treatment is necessary to prevent further progression of the disease (Ramesh, Sheeja S. Varghese, *et al.*, 2016), (Ramamurthy and Mg, 2018). There are several studies in which researchers have attempted various clinical trials for regenerative methods using PRF, Growth factors and stem cells (Avinash, Malaippan and Dooraiswamy, 2017), (Panda *et al.*, 2014), (Mootha *et al.*, 2016), (Ravi *et al.*, 2017), (Khalid, 2017), (Khalid *et al.*, 2016), and numerous in-vitro studies for the treatment of periodontitis were evaluated over the past 5 years (Kavarthapu and Thamaraiselvan, 2018), (Ramesh, Ravi and Kaarthikeyan, 2017), (Ramesh *et al.*, 2019), (Priyanka *et al.*, 2017), (Thamaraiselvan *et al.*, 2015).

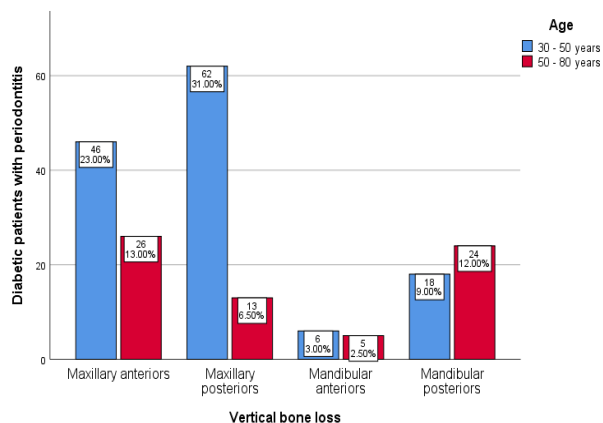
Successful periodontal therapy depends on many factors. One of the most significant factors is the identification of the pattern of periodontal bone destruction so as to plan the treatment procedures. Therefore, this study evaluates the vertical bone loss seen in diabetic patients with periodontitis among the selected population. Among 10,000 case records evaluated, a total of two hundred patients with chronic periodontitis who sustain diabetes mellitus were taken into the study. Vertical bone loss among each patient was assessed. Frequency distribution of vertical bone loss among the diabetic patients with chronic periodontitis infers that vertical bone loss seen in maxillary posteriors (37.5%) was higher than the bone

loss seen among maxillary anteriors(36%), mandibular anteriors(5.50%) and posteriors (21%) (Graph-1).



Graph 1: Bar graph represents frequency of distribution of vertical bone loss among the diabetic patients with chronic periodontitis. X axis represents vertical bone loss. Y axis represents diabetic patients with chronic periodontitis. Vertical bone loss is commonly seen among maxillary posteriors(orange) than other types of teeth [Maxillary anteriors(dark blue), Mandibular anteriors (Purple) and posteriors(yellow)] among diabetic patients with chronic periodontitis.

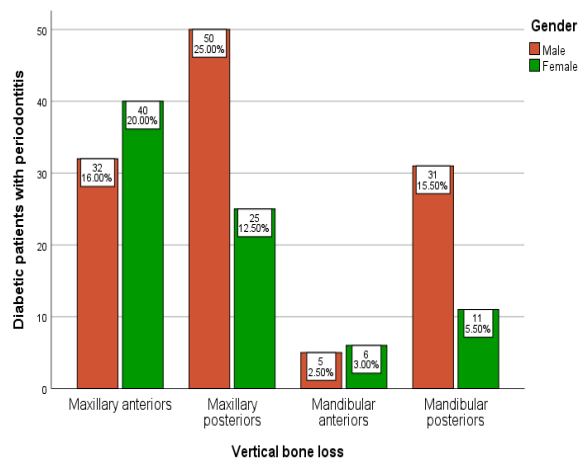
Similarly, Larato reported that vertical bone defects are more commonly found on the mesial surfaces of the upper and lower molars(Larato, 1970). However, Papapanou presented a different picture regarding the location of defects, asserting that premolars appeared to have a higher prevalence of vertical defects than other teeth(Papapanou, Wennström and Gröndahl, 1988).Whereas, page et al stated that overall vertical bone loss pattern in his study was about 28% whereas it was 26.3% horizontal bone loss pattern in the mesial portion and 21.2% in the distal portion(Page and Kornman, 1997).



Graph 2: Bar graph represents association between age and vertical bone loss seen among the diabetic patients with chronic periodontitis. X axis represents vertical bone loss. Y axis represents diabetic patients with chronic periodontitis. Vertical bone loss was more prevalent among diabetic patients with chronic periodontitis among the age group of 30 to 50 years (blue) than patients under 50 to 80 years of age group(red). P value = 0.001 was statistically significant, proving an association between age and vertical bone loss.

Graph 2 represents the association between age distribution and vertical bone loss seen among the diabetic patients with chronic periodontitis.Among the patients under the age group of 30 to 50 years, 23% of the patients had vertical bone loss in maxillary anteriors, 31% of the patients had vertical bone loss in maxillary posteriors, 3% of them had vertical bone loss in mandibular anteriors and for 9% of them vertical bone loss was seen in mandibular posteriors. Among the patients who are under 50 to 80 years of age group , 13% of the patients had vertical bone loss in maxillary anteriors, 6.5% of the patients had vertical bone loss in maxillary posteriors, 2.5% of them had vertical bone loss in mandibular anteriors and for 12% of them vertical bone loss was seen in mandibular posteriors. P = 0.001 which was considered to be statistically significant. Similar to our studies, Ozcan et al stated that the mean age of the patients was 43.7 , with ages

ranging from 20 to 75 years who had vertical and horizontal patterns of bone destruction (Ozcan and Sekerci, 2017), (Sima *et al.*, 2012). In this study, the association between gender distribution and vertical bone loss among the diabetic patients with chronic periodontitis was assessed. Among males, 16% of them had vertical bone loss in maxillary anteriors, 25% of them had this defect in maxillary posteriors, 2.5% of them had vertical bone loss in mandibular anteriors and for 15.5% of the patients vertical bone loss was seen in mandibular posteriors. Among females, 20% of them had vertical bone loss in maxillary anteriors, 12.5% of them had this defect in maxillary posteriors, 3% of them had vertical bone loss in mandibular anteriors and for 5.5% of the patients, vertical bone loss was seen in mandibular posteriors. $P = 0.005$ which was considered to be statistically significant (Graph -3).



Graph 3: Bar graph represents the association between gender distribution and vertical bone loss among the diabetic patients with chronic periodontitis. X axis represents vertical bone loss. Y axis represents diabetic patients with chronic periodontitis. Vertical bone loss pattern was more prevalent among the male (brown) diabetic patients with chronic periodontitis than females (green). P value = 0.005 which was considered to be statistically significant, proving there is an association between gender and vertical bone loss.

Published by: The Mattingley Publishing Co., Inc.

Similar to our results, helmi *et al* indicate that males have a higher risk of developing periodontal diseases with significantly higher alveolar bone loss compared to females (Helmi *et al.*, 2019).

Bone loss is mainly caused due to the reduced bone calcium levels which occurs due to insulin deficiency. Both of these conditions cause alveolar bone resorption (Fukuda *et al.*, 2008). There are several limitations in this study as the sample size is restricted only to an institution. Therefore, larger study could have been assessed among different geographic locations, for more accuracy comparison with non-diabetic patients was not done. These factors should be evaluated in order to draw more representative results (Susanto *et al.*, 2011).

CONCLUSION

This study concludes that vertical bone loss was found more prevalently in maxillary posterior tooth region among chronic periodontitis patients those who had diabetes mellitus. It was commonly seen among males and was profoundly found in the age group of 30 to 50 years. It might occur due to bone damage that developed in a long span of time period and without any proper treatment measures. Vertical bone loss is the most common problem confronting the clinician but has been receiving scant attention. Research should be directed towards regeneration of lost alveolar bone. Novel technologies using tissue engineering (growth factors and stem cells) and miniature bone pins may emerge as treatment options in the future, as vertical bone loss with well-entrenched trough-like defects is only being eligible for regenerative procedure, it should be assessed in its earlier stage of progression of the defect to avoid leading it to complete bone destruction among the diabetic patients with chronic periodontitis.

ACKNOWLEDGEMENT

The authors would like to thank the study participants for their participation and Saveetha Dental College for providing a platform to express our knowledge.

CONFLICT OF INTEREST

The authors declare that there were no conflicts of interest in the present study.

REFERENCES

1. Association, A. D. and American Diabetes Association (2005) 'Diagnosis and Classification of Diabetes Mellitus', *Diabetes Care*, pp. S37–S42. doi: 10.2337/diacare.28.suppl_1.s37.
2. Avinash, K., Malaippan, S. and Dooraiswamy, J. N. (2017) 'Methods of Isolation and Characterization of Stem Cells from Different Regions of Oral Cavity Using Markers: A Systematic Review', *International Journal of Stem Cells*, pp. 12–20. doi: 10.15283/ijsc17010.
3. Bacić, M., Plancak, D. and Granić, M. (1988) 'CPITN assessment of periodontal disease in diabetic patients', *Journal of periodontology*, 59(12), pp. 816–822.
4. Bell, G. I. and Polonsky, K. S. (2001) 'Diabetes mellitus and genetically programmed defects in beta-cell function', *Nature*, 414(6865), pp. 788–791.
5. Campus, G. *et al.* (2005) 'Diabetes and periodontal disease: a case-control study', *Journal of periodontology*, 76(3), pp. 418–425.
6. Fukuda, C. T. *et al.* (2008) 'Radiographic Alveolar Bone Loss in Patients Undergoing Periodontal Maintenance', *The Bulletin of Tokyo Dental College*, pp. 99–106. doi: 10.2209/tdcpublication.49.99.
7. Helmi, M. F. *et al.* (2019) 'Prevalence of periodontitis and alveolar bone loss in a patient population at Harvard School of Dental Medicine', *BMC Oral Health*. doi: 10.1186/s12903-019-0925-z.
8. Kaul, K. *et al.* (2012) 'Introduction to diabetes mellitus', *Advances in experimental medicine and biology*, 771, pp. 1–11.
9. Kavarthapu, A. and Thamaraiselvan, M. (2018) 'Assessing the variation in course and position of inferior alveolar nerve among south Indian population: A cone beam computed tomographic study', *Indian Journal of Dental Research*, p. 405. doi: 10.4103/ijdr.ijdr_418_17.
10. Khalid, W. *et al.* (2016) 'Role of endothelin-1 in periodontal diseases: A structured review', *Indian journal of dental research: official publication of Indian Society for Dental Research*, 27(3), pp. 323–333.
11. Khalid, W. (2017) 'Comparison of Serum Levels of Endothelin-1 in Chronic Periodontitis Patients Before and After Treatment', *Journal of clinical and diagnostic research*. doi: 10.7860/jcdr/2017/24518.9698.
12. Larato, D. C. (1970) 'Intrabony Defects in the Dry Human Skull', *Journal of Periodontology*, pp. 496–498. doi: 10.1902/jop.1970.41.9.496.
13. Mealey, B. L. and Ocampo, G. L. (2007) 'Diabetes mellitus and periodontal disease', *Periodontology 2000*, 44, pp. 127–153.
14. Mootha, A. *et al.* (2016) 'The Effect of Periodontitis on Expression of Interleukin-21: A Systematic Review', *International Journal of Inflammation*, pp. 1–8. doi: 10.1155/2016/3507503.
15. Nainggolan, L. I. and Gunasagaran, L. (2018) 'Prevalence of alveolar bone defect pattern in periodontitis patients with diabetes mellitus using bitewing radiography', *Journal of Dentomaxillofacial Science*, p. 88. doi: 10.15562/jdmfs.v3i2.739.
16. Ozcan, G. and Sekerci, A. E. (2017)

- ‘Classification of alveolar bone destruction patterns on maxillary molars by using cone-beam computed tomography’, *Nigerian journal of clinical practice*, 20(8), pp. 1010–1019.
17. Page, R. C. and Kornman, K. S. (1997) ‘The pathogenesis of human periodontitis: an introduction’, *Periodontology* 2000, pp. 9–11. doi: 10.1111/j.1600-0757.1997.tb00189.x.
 18. Panda, S. *et al.* (2014) ‘Platelet rich fibrin and xenograft in treatment of intrabony defect’, *Contemporary clinical dentistry*, 5(4), pp. 550–554.
 19. Papapanou, P. N., Wennström, J. L. and Gröndahl, K. (1988) ‘Periodontal status in relation to age and tooth type. A cross-sectional radiographic study’, *Journal of clinical periodontology*, 15(7), pp. 469–478.
 20. Priyanka, S. *et al.* (2017) ‘Detection of cytomegalovirus, Epstein-Barr virus, and Torque Teno virus in subgingival and atheromatous plaques of cardiac patients with chronic periodontitis’, *Journal of Indian Society of Periodontology*, 21(6), pp. 456–460.
 21. Ramamurthy, J. and Mg, V. (2018) ‘Comparison of effect of hiora mouthwash versus chlorhexidine mouthwash in gingivitis patients: A clinical trial’, *Asian Journal of Pharmaceutical and Clinical Research*, p. 84. doi: 10.22159/ajpcr.2018.v11i7.24783.
 22. Ramesh, A., Varghese, S. S., *et al.* (2016) ‘Chronic obstructive pulmonary disease and periodontitis – unwinding their linking mechanisms’, *Journal of Oral Biosciences*, pp. 23–26. doi: 10.1016/j.job.2015.09.001.
 23. Ramesh, A., Varghese, S. S., *et al.* (2016) ‘Herbs as an antioxidant arsenal for periodontal diseases’, *Journal of intercultural ethnopharmacology*, 5(1), pp. 92–96.
 24. Ramesh, A. *et al.* (2019) ‘Esthetic lip repositioning: A cosmetic approach for correction of gummy smile – A case series’, *Journal of Indian Society of Periodontology*, p. 290. doi: 10.4103/jisp.jisp_548_18.
 25. Ramesh, A., Ravi, S. and Kaarthikeyan, G. (2017) ‘Comprehensive rehabilitation using dental implants in generalized aggressive periodontitis’, *Journal of Indian Society of Periodontology*, p. 160. doi: 10.4103/jisp.jisp_213_17.
 26. Ravi, S. *et al.* (2017) ‘Additive Effect of Plasma Rich in Growth Factors With Guided Tissue Regeneration in Treatment of Intrabony Defects in Patients With Chronic Periodontitis: A Split-Mouth Randomized Controlled Clinical Trial’, *Journal of Periodontology*, pp. 839–845. doi: 10.1902/jop.2017.160824.
 27. Ryan, M. E. *et al.* (1999) ‘MMP-mediated events in diabetes’, *Annals of the New York Academy of Sciences*, 878, pp. 311–334.
 28. Sima, C. *et al.* (2012) ‘Periodontitis in Patients with Diabetes A Complication that Impacts on Metabolic Control’, *US Endocrinology*, p. 35. doi: 10.17925/use.2012.08.01.35.
 29. Susanto, H. *et al.* (2011) ‘Periodontitis prevalence and severity in Indonesians with type 2 diabetes’, *Journal of periodontology*, 82(4), pp. 550–557.
 30. Thamaraiselvan, M. *et al.* (2015) ‘Comparative clinical evaluation of coronally advanced flap with or without platelet rich fibrin membrane in the treatment of isolated gingival recession’, *Journal of Indian Society of Periodontology*, 19(1), pp. 66–71.
 31. Varghese, S. *et al.* (2015) ‘Estimation of salivary tumor necrosis factor-alpha in chronic and aggressive periodontitis patients’, *Contemporary Clinical Dentistry*, p. 152. doi: 10.4103/0976-237x.166816.
 32. Zimmet, P., Alberti, K. G. and Shaw, J. (2001) ‘Global and societal implications of the diabetes

epidemic', *Nature*, 414(6865), pp. 782–787.