

Assessment of Gingival Enlargement in Epileptic patients - A Retrospective study

Running title: Gingival Enlargement in Epileptic patients

SuhasManoharan

*Saveetha Dental College,
Saveetha institute of Medical and Technical sciences
Saveetha University, Chennai, India
Mail ID: suhaas97@gmail.com*

SreedeviDharman

Reader

*Department of Oral Medicine and radiology
Saveetha Dental College,
Saveetha institute of Medical and Technical sciences
Saveetha University, Chennai, India
Mail id: sreedevi@saveetha.com*

Aravind Kumar S

*Professor, Department of Orthodontics,
Saveetha Dental College,
Saveetha institute of Medical and Technical sciences
Saveetha University, Chennai, India
Mail id: aravindkumar@saveetha.com*

Corresponding Author:

SreedeviDharman

Reader

*Department of Oral Medicine and radiology, Saveetha Dental College,
Saveetha institute of Medical and Technical sciences
Saveetha University, 162, Poonamallee High Road
Chennai 600077, Tamil Nadu, India
Mail id: sreedevi@saveetha.com*

Article Info**Volume 83****Page Number: 2385 - 2396****Publication Issue:****July-August 2020****Abstract:**

Epilepsy is a neurological disorder with recurrent seizures in patients due to underlying chronic disease. Medications taken by epileptics can cause gingival enlargement. Gingival enlargement is aesthetically undesirable and causes difficulty in mastication, speech. The aim of the study was to assess the association of age, gender in epileptic patients with gingival enlargement. A retrospective study for presence of gingival enlargement in epileptic patients was reviewed from patient records and analyzing the case sheets between June 2019 and March 2020 in dental outpatient department. Age groups of patients involved in the study are 20-35 years, 35-50 years and 50-65 years. Patient age, gender, type of gingival enlargement was also collected. Excel tabulation was done and results obtained from SPSS version 20. Statistical test performed was chi square analysis to find the association of gingival enlargement types with age, gender of epileptic patients. 118 case sheets were studied out of which 70 were females and 48 were Males. Only 8% of the total study group showed epilepsy related drug induced gingival enlargement. Gingival enlargement of generalized type was seen commonly in males (3.42%) $p=0.063$ ($p>0.05$) statistically not significant, in the age group of 20-35 years (2.85%) P value - 0.696 ($p>0.05$), not statistically significant and localized among both genders in the age group of 20-35 years (1.89%). Periodontal disease was more in generalized gingival enlargement but not significantly associated, p value - 0.788 ($p>0.05$), not statistically significant. Within the limits of the study, a small percentage of epileptic patients had drug induced gingival enlargement. Males showed comparatively higher distribution of generalized gingival enlargement in epileptic patients. Periodontal pathologies were common in epileptic patients with gingival enlargement.

Keywords: Epilepsy, gingival Enlargement, aesthetics, growth, phenytoin

Article History**Article Received: 06 June 2020****Revised: 29 June 2020****Accepted: 14 July 2020****Publication: 25 July 2020****INTRODUCTION**

Epilepsy is a neurological disorder that affects 1 - 3 % of the world's population (Gurbuz and Tan, 2010). Epilepsy is a brain disorder that occurs at any point in life. However its incidence among young population has decreased in the past decades. (Duncan *et al.*, 2006). Apart from other neurological disorders, public stigma has marked epilepsy out. (Duncan *et al.*, 2006). Many classifications are present to categorize various types of epilepsy. An epileptic attack usually originates from the cortex or sub cortex of the brain. After assessment of patient history and EEG reports a physician may classify a seizure or epilepsy based on which the course of treatment is planned. The main types of epilepsy are tonic clonic, myoclonic, atonic and absence seizures (Muro and Connolly, 2014). Absence seizures

are also called as petit mal which characteristically involves staring and unresponsiveness eyes along with occasional nodding of the head and blinking of the eyes. Grand mal seizures involve convulsive movements that are symmetric and bilateral in nature, usually accompanied with loss of consciousness. Atonic seizures cause loss of body tone resulting in drooping of the head. Myoclonic seizures show sudden, rapid jerks or movements without loss of consciousness. Such seizures can be focal or generalized as they can affect one or multiple muscle groups ('Epilepsy: A Comprehensive Textbook, Vol 1, 2nd ed', 2008). The drug induced gingival enlargement begins as a bead shaped inflammation or growth in the marginal, interdental papilla areas which gradually involves the marginal gingiva. If there is absence of any

secondary inflammation, the enlargement resembles a mulberry, pink, firm and resilient in nature. Bleeding on probing is absent (Willmore, 1991). It is also noted that drug-induced gingival enlargement is most common in the anterior of maxilla and mandible. Epilepsy management may require changes in lifestyle along with certain medications. Various drugs can lead to gingival enlargement. Drugs such as immunosuppressants, anticonvulsants, and calcium channel blockers may be related to the presentation of gingival enlargement. Gingival enlargement usually considered as a side effect is 2-3 months after drug intake. This enlargement is not painful in most cases but is of discomfort and aesthetically not pleasing. (Bharti and Bansal, 2013)

Gingival enlargement or gingival overgrowth, is a common marker for gingival disease. Management of gingival enlargement depends on etiology of the enlargement. Gingival enlargement may be localised or generalised. ('Epilepsy: A Comprehensive Textbook, Vol 1, 2nd ed', 2008) Generalised gingival enlargement is most common due to certain drugs that are used in epilepsy management. Gingival enlargement can lead to undesirable aesthetics and difficulty in mastication in a few cases. Hence early diagnosis and knowledge regarding this field is necessary to provide better patient care.

According to (Nayyar *et al.*, 2012), Phenytoin is linked with gingival enlargements and incidence is fairly common. As a general rule, epilepsy medication must be given in low doses to prevent any side effects. Most anti-epileptic drugs cause CNS side effects which are undesirable (Bui *et al.*, 2015). (Somasundara *et al.*, 2016) claimed 29% cases with epilepsy and consumed phenytoin developed moderate gingival enlargement. Previously our team had conducted numerous case studies (Choudhury and Panigrahi, 2015; Misra *et al.*, 2015; Dharman and Muthukrishnan, 2016; Muthukrishnan, Kumar and Ramalingam, 2016; Muthukrishnan and Kumar, 2017) and systematic

reviews (Venugopal and Maheswari, 2016; Chaitanya *et al.*, 2017, 2018; Maheswari *et al.*, 2018) and questionnaire-based studies (Subashri and Maheshwari, 2016; Warnakulasuriya and Muthukrishnan, 2018) and international validation study (Steele *et al.*, 2015) and radiographic studies (Rohini and Kumar, 2017; Patil *et al.*, 2018; Subha and Arvind, 2019) over the past 5 years. Hence a current study regarding the patterns of incidence of gingival enlargement associated with epilepsy can be done and may be used to find an alternate drug for patients in such cases. The aim of the study was to assess the association of age, gender in epileptic patients with gingival enlargement.

MATERIALS AND METHODS

Study design and setting:

The study was conducted in a University set up in a Private dental College, Chennai carried out after obtaining approval from the institutional review board. A retrospective study was conducted on patients who visited Saveetha dental College. The patient records were reviewed and analysed between June 2019 and March 2020. All available data was included in the study to minimise sampling bias. A total of 2843 case sheets referred to special care dentistry were reviewed from which 107 epileptic patients who were under anti-epileptic medications were included. The advantage of this study was the flexible data that could be obtained easily and economically. However, the drawback of this study is that there were geographic limitations and the people involved in the study were from an isolated population and belonged to the same ethnic group.

Data collection

107 patients were included in the study based on the inclusion and exclusion criteria. All patients with history of epilepsy under anti-epileptic drugs were included in the study. Patients with gingival enlargement due to local factors without any history of epilepsy and case sheets with incomplete data were

excluded. Age groups of patients involved in the study are 20-35 years, 35-50 years and 50-65 years. Data collected were age, gender, type of gingival enlargement and periodontal status. Collected data was cross verified using photos and case sheets. Data collected was then tabulated. All data was collected and tabulated methodically using MS Excel.

Statistical Analysis

After tabulation using MS Excel, the data was exported to IBM SPSS software [Version 20: IBM Corporation NY USA] for statistical analysis. Dependent variable are gingival enlargement, independent variable were age and gender, periodontal status. Descriptive statistics was used to determine the frequencies of gender and age distribution of epileptic patients. Chi square analysis to

assess the association of gingival enlargement (Generalised and localised) with age, gender, periodontal status in epileptic patients. Pearson chi square test was used to identify any significant level of association, significance level was set at 0.05

Ethical Approval

The ethical approval for the retrospective study was obtained from the institutional ethics board. Ethical approval number: SDC/SIHEC/2020/DIASDATA/0619-0320.

RESULTS AND DISCUSSION

Out of the total study group of 118 epileptic patients, 8% of the patients showed gingival enlargement. Figure 1

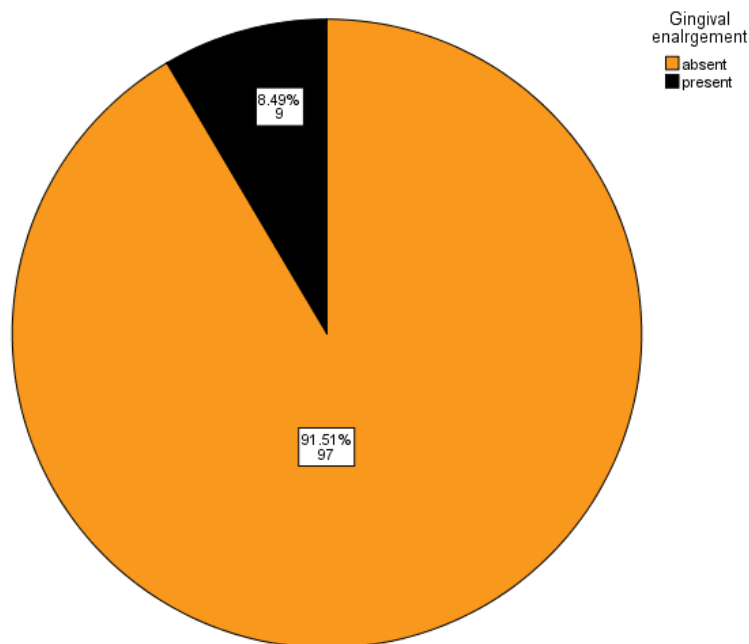


Figure 1: Pie chart depicting the distribution of gingival enlargement in patients with history of epilepsy. Only 8% of the epileptic patients had drug induced gingival enlargement (black).

shows that only 8% of the total study group showed epilepsy related drug induced gingival enlargement.

Figure 2 shows that patients in the age group of 20-35

years(45.28%) more commonly presented with a history of epilepsy

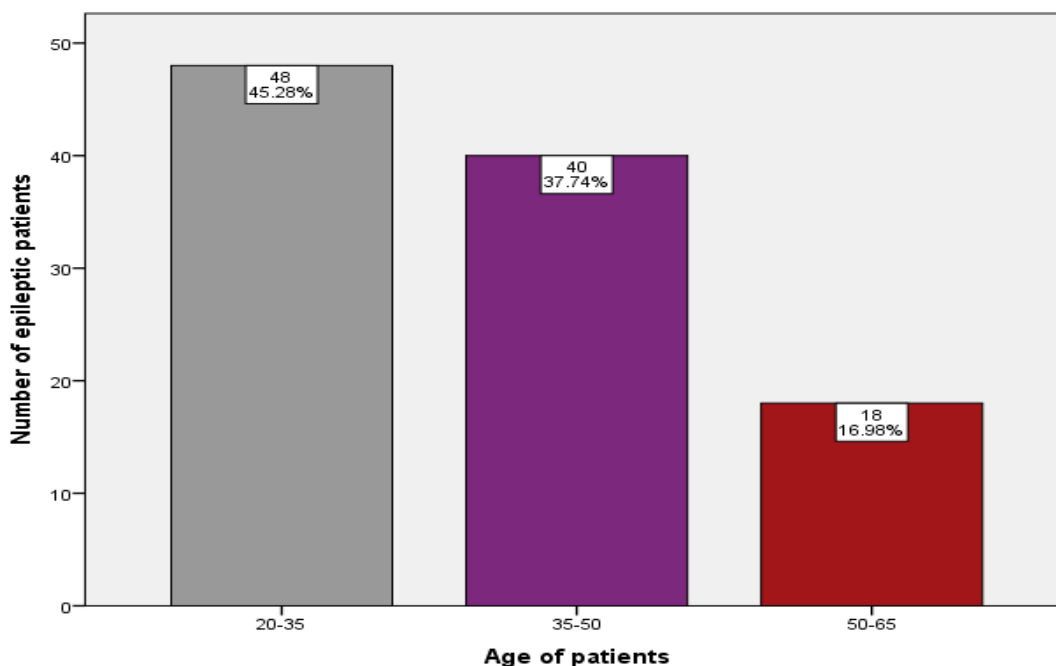


Figure 2: Bar chart depicting the age distribution of epileptic patients. X axis depicts the age of patients. Y axis represents the number of epileptic patients. Patients in the age group of 20-35 years(Grey)45.28% had more epileptic patients compared to other age groups

Figure 3 shows that female patients more commonly presented with a history of epilepsy(63.21%), Figure 4 shows generalised gingival enlargement was seen only among 19-35 years(2.83%) and 36-55(0.94%) years age groups. P value - 0.696($p > 0.05$) which is statistically not significant

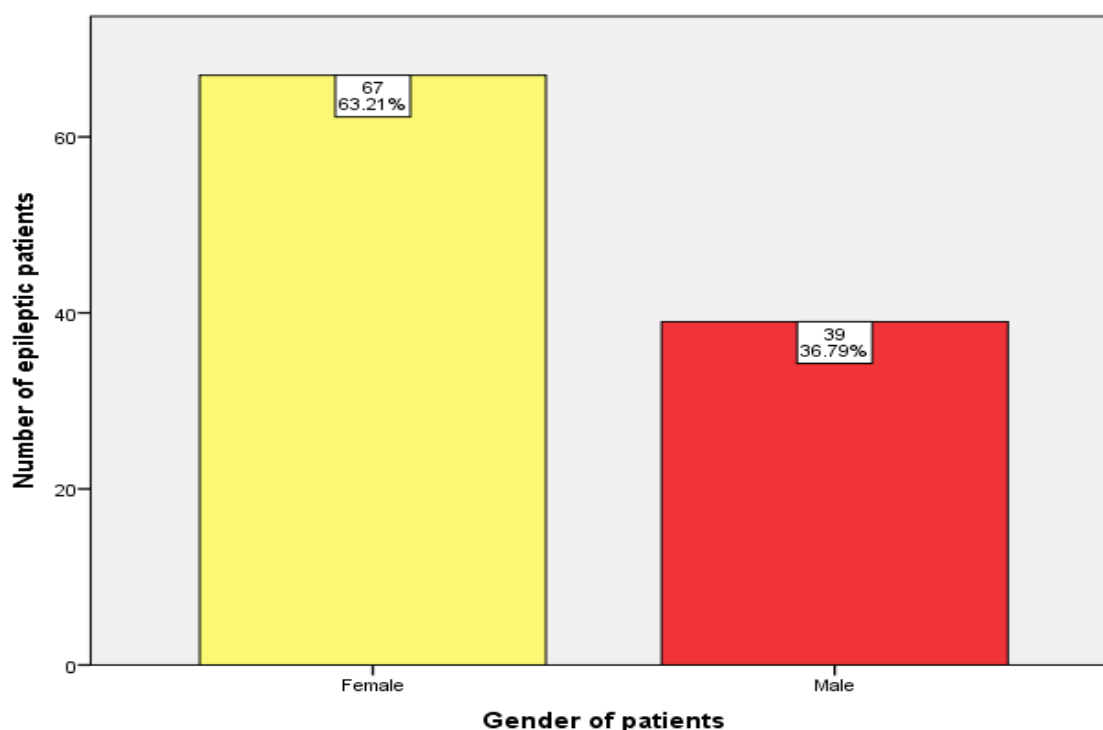


Figure 3: Bar chart depicting the gender distribution of epileptic patients. X axis depicts the gender of patients. Y axis represents the number of epileptic patients. In the total study sample majority were Females(Yellow) 63.21% followed by males(red)36.79%

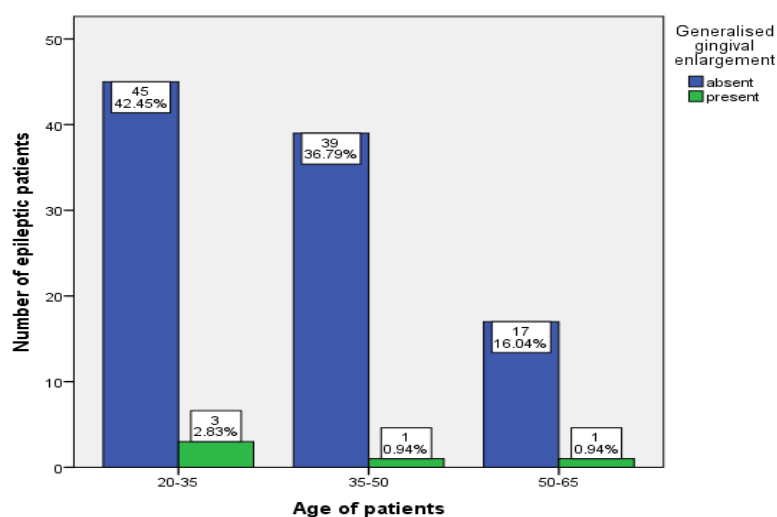


Figure 4: Bar chart depicting the association of age and generalised gingival enlargement in epileptic patients. X axis depicts the age of patients. Y axis represents the number of epileptic patients. Majority of generalised gingival enlargement among epileptic patients was present(green) in 20-35 years compared to other age groups. Chi square analysis done. P value - 0.696 ($p > 0.05$) statistically not significant.

Figure 5 shows that males showed comparatively higher distribution of generalised gingival enlargement (3.42%) p value-0.063($p>0.05$).

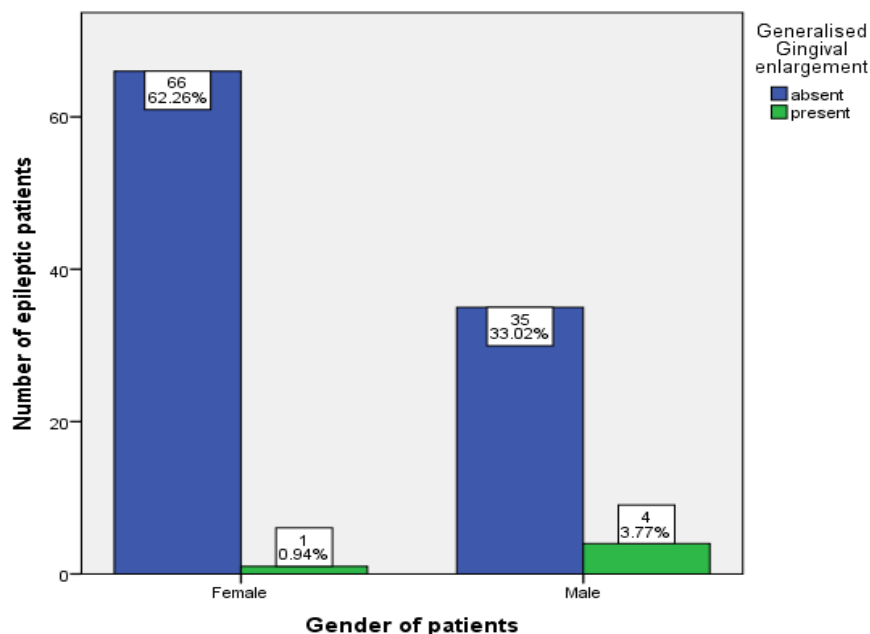


Figure 5: Bar chart depicting the association of gender and generalised gingival enlargement in epileptic patients. X axis depicts the gender of patients. Y axis represents the number of epileptic patients. Males showed comparatively higher distribution of generalised gingival enlargement (present-green) in epileptic patients compared to females. Chi square analysis done. P value - 0.063($p>0.05$) statistically not significant

Figure 6 shows localised gingival enlargement in 20-35 years (1.89%) and 35-50 years (1.89%) compared to epileptic patients was commonly present in other age groups. p value-0.646($p>0.05$).

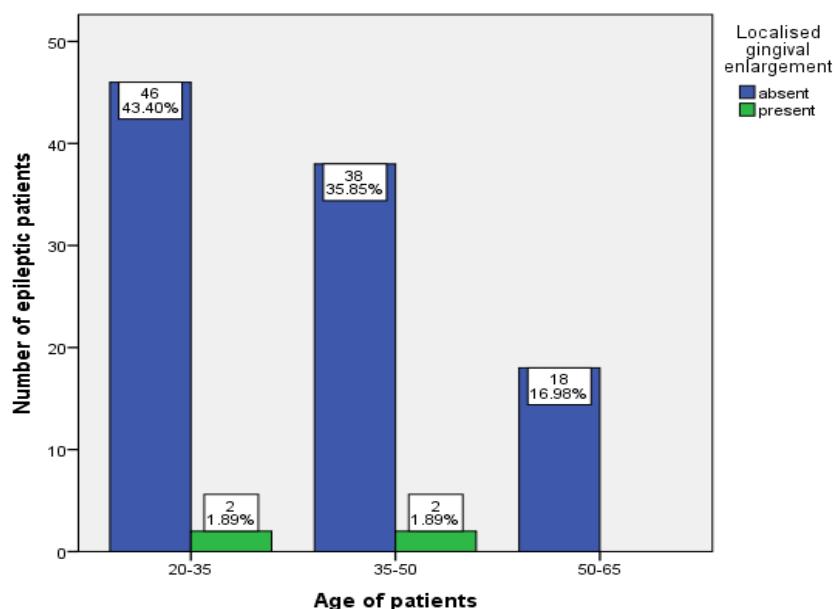


Figure 6: Bar chart depicting the association of age and localised gingival enlargement in epileptic patients. X axis depicts the age of patients. Y axis represents the number of epileptic patients. Localised gingival enlargement in epileptic patients was commonly present (green) in 20-35 years and 35-50 years compared to other age groups. Chi square analysis done. P value - 0.646 ($p > 0.05$) statistically not significant.

Figure 7 shows that both genders showed similar p value- 0.355 ($p > 0.05$), which is statistically not significant.

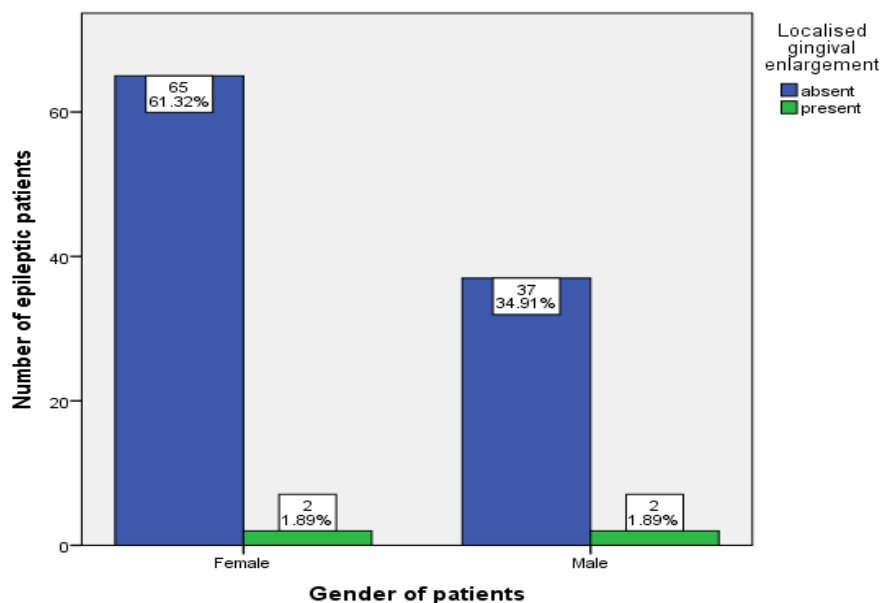


Figure 7: Bar chart depicting the association of gender and localised gingival enlargement in epileptic patients. X axis depicts the gender of patients. Y axis represents the number of epileptic patients. Localised gingival

enlargement in epileptic patients was commonly present (green) both in male and female patients. Chi square analysis done. P value - 0.335 ($p > 0.05$) statistically not significant.

Figure 8 shows that both genders showed higher enlargement. p value- 0.788 ($p > 0.05$), which is statistically not significant.

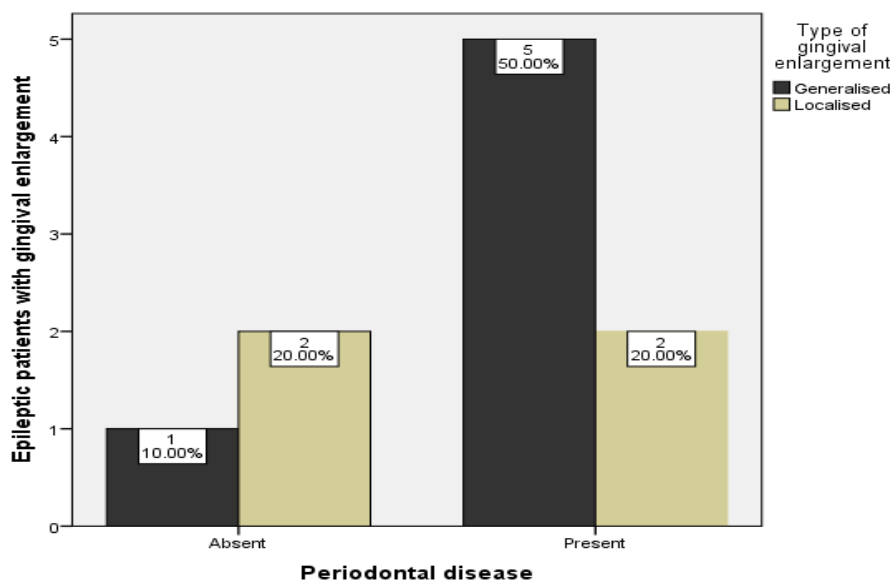


Figure 8: Bar chart depicting the association of gingival enlargement in epileptic patients and periodontal status of patients. X axis depicts the periodontal status of patients. Y axis shows epileptic patients with gingival enlargement. Epileptic patients with Generalised gingival enlargement had more periodontal disease compared to patients with localised gingival enlargement. Chi square analysis done. p value- 0.788 which is statistically not significant.

Out of the total study group of 118 epileptic patients, 8% of the patients showed gingival enlargement. All the patients were antiepileptic medication mostly phenytoin compared to cyclosporine and calcium channel blockers. (Gurbuz and Tan, 2010) and (Goyal, 2017) proved phenytoin and sodium valproate administered for epileptic is a predisposition to gingival enlargement. In contrast to our study, severity of gingival enlargement was found to be higher in (Akiyama *et al.*, 2006) which showed 33 % of patients experienced gingival enlargement with

phenytoin. Another Nigerian study (Ogunbodede, Adamolekun and Akintomide, 1998) showed 83.3 % prevalence of gingival enlargement in epileptic patients with phenytoin and phenobarbital therapy. It was also suggested that young age can increase the risk of drug induced gingival enlargement (Majola *et al.*, 2000). Similarly our study showed most epileptic patients were around the age group of 25-30 years. A south african study showed a statistically significant relation of age to gingival enlargement due to phenytoin, however no such significant correlation was found in

the current study(Majolaet *al.*, 2000) .A study conducted in bangalore,India(Nayyaret *al.*, 2012)showed that 76% males tend to have epilepsy however in contrast,the current study showed females (63.21%)to have a higher incidence of epilepsy than males(36.79%).(Lin, Laura M F and Yacubian, 2007) claimed that gingival enlargement varies in incidence from 3% to 93% depending on ethnicity compared to the results of our study which showed almost 8% incidence of gingival enlargement either localised or generalised in our population.The study also claimed that generalised gingival enlargement was mostly due to phenytoin commonly administered for management of epileptic patients(Nayyaret *al.*, 2014).In our study,generalised gingival enlargement was seen only among 19-35 years and 36-55 years age groups. Males showed comparatively higher distribution of generalised gingival enlargement (3.42%) and both genders showed similar distribution of localised gingival enlargement. Localised gingival enlargement in epileptic patients was commonly present in 20-35 years and 35-50 years. Our study showed most patients with generalised gingival enlargement had periodontal disease.(Fernandeset *al.*, 2010) claimed that gingival enlargement in rats due to nifedipine can be linked with periodontal breakdown.

Studies showed that gingival enlargement due to immunosuppressive drugs like cyclosporine are more richly vascularized than enlargements due to phenytoin.(Duchowny, Cross and Arzimanoglu, 2012)Gingival enlargement may have many causative factors, however gingival enlargements can easily be diagnosed by proper history taking to check if its hormonal or drug induced, by location of enlargement or by clinical manifestation of gingival enlargement. Local factors such as plaque and calculus can also lead to gingival enlargement. Initial plaque control and oral hygiene methods should be adopted to rule enlargement due local irritant factors.Inrare cases histological analysis or biopsy may be required to diagnose the type

of enlargement.All possible etiologies should be considered by the clinician to ensure efficient treatment is delivered to the patient.

Limitations of study, the results of the study can not be generalized to a larger population and other ethinc groups. A study including more patients reviewed over a longer time span and patients of various ethnic groups can give better and more accurate results .

CONCLUSION

Within the limits of the study,a small percentage of epileptic patients had drug induced gingival enlargement. Males of 20-35 years were more commonly affected with generalised gingival enlargement. Gingival enlargement in epileptic patients was not significantly associated with periodontal disease. Gingival enlargement hinders proper oral hygiene maintenance,along with esthetic disfigurement,difficulty in mastication and hence patient awareness and motivation with early management is warranted.

CONFLICT OF INTEREST: The authors have no conflict of interest.

AUTHOR CONTRIBUTIONS

SuhasManoharan carried out the retrospective study, planning the study design, collection and analysis of data and drafted the manuscript.SreedeviDharman and Aravind Kumar S aided in conception of the topic, supervision and appraisal of the manuscript.

ACKNOWLEDGEMENT

The study was supported by Saveetha Dental College and Hospitals who provided insights and expertise that greatly assisted the study.

REFERENCES

1. Akiyama, S. *et al.* (2006) 'Relationship of periodontal bacteria and Porphyromonas gingivalis fimA variations with phenytoin-induced gingival overgrowth', *Oral diseases*. Wiley Online Library, 12(1), pp. 51–56.
2. Bharti, V. and Bansal, C. (2013) 'Drug-induced gingival overgrowth: The nemesis of gingiva unravelled', *Journal of Indian Society of Periodontology*, 17(2), pp. 182–187.
3. Bui, A. *et al.* (2015) 'Microcircuits in Epilepsy: Heterogeneity and Hub Cells in Network Synchronization', *Cold Spring Harbor perspectives in medicine*, 5(11). doi: 10.1101/cshperspect.a022855.
4. Chaitanya, N. C. *et al.* (2017) 'Role of vitamin E and vitamin a in oral mucositis induced by cancer chemo/radiotherapy-a meta-analysis', *Journal of clinical and diagnostic research: JCDR*. JCDR Research & Publications Private Limited, 11(5), p. ZE06.
5. Chaitanya, N. C. *et al.* (2018) 'An insight and update on the analgesic properties of vitamin C', *Journal of pharmacy & bioallied sciences*. Wolters Kluwer--Medknow Publications, 10(3), p. 119.
6. Choudhury, P. and Panigrahi, R. G. (2015) 'Vanishing roots: first case report of idiopathic multiple cervico-apical external root resorption', *Journal of clinical and*. ncbi.nlm.nih.gov. Available at: <https://www.ncbi.nlm.nih.gov/pmc/articles/PMC4413163/>.
7. Dharman, S. and Muthukrishnan, A. (2016) 'Oral mucous membrane pemphigoid – Two case reports with varied clinical presentation', *Journal of Indian Society of Periodontology*, p. 630. doi: 10.4103/jisp.jisp_155_16.
8. Duchowny, M., Cross, H. and Arzimanoglou, A. (2012) *Pediatric Epilepsy*. McGraw Hill Professional.
9. Duncan, J. S. *et al.* (2006) 'Adult epilepsy', *The Lancet*, 367(9516), pp. 1087–1100.
10. 'Epilepsy: A Comprehensive Textbook, Vol 1, 2nd ed' (2008) *Archives of neurology*. American Medical Association, 65(12), pp. 1676–1677.
11. Fernandes, M. I. *et al.* (2010) 'Effect of nifedipine on gingival enlargement and periodontal breakdown in ligature-induced periodontitis in rats', *Archives of oral biology*, 55(7), pp. 523–529.
12. Goyal, L. (2017) 'Periodontal Management of Phenytoin Induced Gingival Enlargement: A Case Report', *Journal of Dental Health, Oral Disorders & Therapy*. doi: 10.15406/jdhodt.2017.08.00271.
13. Gurbuz, T. and Tan, H. (2010) 'Oral health status in epileptic children', *Pediatrics international: official journal of the Japan Pediatric Society*, 52(2), pp. 279–283.
14. Lin, K., Laura M F and Yacubian, E. M. T. (2007) 'Drug-induced gingival enlargement - Part II. Antiepileptic drugs: not only phenytoin is involved', *Journal of Epilepsy and Clinical Neurophysiology*, pp. 83–88. doi: 10.1590/s1676-26492007000200009.
15. Maheswari, T. N. U. *et al.* (2018) 'Salivary micro RNA as a potential biomarker in oral potentially malignant disorders: A systematic review', *Tzu-Chi Medical Journal*. Wolters Kluwer--Medknow Publications, 30(2), p. 55.
16. Majola, M. P. *et al.* (2000) 'Factors influencing phenytoin-induced gingival enlargement', *Journal of clinical periodontology*. Wiley Online Library, 27(7), pp. 506–512.
17. Misra, S. R. *et al.* (2015) 'Metastatic hepatocellular carcinoma in the maxilla and mandible, an extremely rare presentation', *Contemporary clinical dentistry*. Wolters Kluwer--Medknow Publications, 6(Suppl 1), p. S117.
18. Muro, V. M. and Connolly, M. B. (2014) 'Classifying epileptic seizures and the epilepsies',

- Epilepsy*. Wiley Online Library, pp. 10–14.
19. Muthukrishnan, A. and Kumar, L. B. (2017) 'Actinic cheilosis: early intervention prevents malignant transformation', *Case Reports*. BMJ Publishing Group, 2017, p. bcr2016218654.
 20. Muthukrishnan, A., Kumar, L. B. and Ramalingam, G. (2016) 'Medication-related osteonecrosis of the jaw: a dentist's nightmare', *Case Reports*. BMJ Publishing Group, 2016, p. bcr2016214626.
 21. Nayyar, A. S. *et al.* (2012) 'Gingival enlargement in epileptic patients on phenytoin therapy-An evidence based approach', *Journal of neurology & neurophysiology*, 3(2), p. 1000127.
 22. Nayyar, A. S. *et al.* (2014) 'Phenytoin, folic acid and gingival enlargement: Breaking myths', *Contemporary clinical dentistry*. ncbi.nlm.nih.gov, 5(1), pp. 59–66.
 23. Ogunbodede, E. O., Adamolekun, B. and Akintomide, A. O. (1998) 'Oral health and dental treatment needs in Nigerian patients with epilepsy', *Epilepsia*, 39(6), pp. 590–594.
 24. Patil, S. R. *et al.* (2018) 'Three-Rooted Mandibular First Molars in a Saudi Arabian Population: A CBCT Study', *Pesquisabrasileiraemodontopediatria e clinicaintegrada*, 18(1), p. 4133.
 25. Rohini, S. and Kumar, V. J. (2017) 'Incidence of dental caries and pericoronitis associated with impacted mandibular third molar-A radiographic study', *Research Journal of Pharmacy and Technology*. A & V Publications, 10(4), pp. 1081–1084.
 26. Somasundara, Y. S. *et al.* (2016) 'Gingival Enlargement and Seizure-related Oro-dental Injuries in Patients with Epilepsy', *INTERNATIONAL JOURNAL OF SCIENTIFIC STUDY*. INT JOURNAL SCIENTIFIC STUDY-IJSS 9-2, SATYALOK BUILDING, GADITAL, HADAPSAR ..., 4(1), pp. 37–42.
 27. Steele, J. C. *et al.* (2015) 'World Workshop on Oral Medicine VI: an international validation study of clinical competencies for advanced training in oral medicine', *Oral surgery, oral medicine, oral pathology and oral radiology*, 120(2), pp. 143–151.e7.
 28. Subashri, A. and Maheshwari, T. N. (2016) 'Knowledge and attitude of oral hygiene practice among dental students', *Research Journal of Pharmacy and Technology*. A & V Publications, 9(11), pp. 1840–1842.
 29. Subha, M. and Arvind, M. (2019) 'Role of magnetic resonance imaging in evaluation of trigeminal neuralgia with its anatomical correlation', *Biomedical and Pharmacology*. biomedpharmajournal.org. Available at: <https://biomedpharmajournal.org/vol12no1/role-of-magnetic-resonance-imaging-in-evaluation-of-trigeminal-neuralgia-with-its-anatomical-correlation/>.
 30. Venugopal, A. and Maheswari, T. N. U. (2016) 'Expression of matrix metalloproteinase-9 in oral potentially malignant disorders: A systematic review', *Journal of Oral and Maxillofacial Pathology*, p. 474. doi: 10.4103/0973-029x.190951.
 31. Warnakulasuriya, S. and Muthukrishnan, A. (2018) 'Oral health consequences of smokeless tobacco use', *Indian Journal of Medical Research*, p. 35. doi: 10.4103/ijmr.ijmr_1793_17.
 32. Willmore, L. J. (1991) 'Epilepsy: Frequency, Causes and Consequences', *Neurology*, pp. 614–614. doi: 10.1212/wnl.41.4.614.