

Patient's Perspective about the Photographs Taken during the Orthodontic Therapy for Documentation

Suhas Manoharan

Saveetha Dental College, Saveetha Institute of Medical and Technical Sciences, Saveetha University, Chennai, India. Mail Id: suhaas97@gmail.com

Remmiya Mary Varghese*

Senior Lecturer, Department of Orthodontics, Saveetha Dental College, Saveetha Institute of Medical and Technical sciences, Saveetha University, Chennai, India. Mail id: remmiyav.sdc@saveetha.com

Aravind Kumar. S

Head of the Department, Department of Orthodontics, Saveetha Dental College, Saveetha Institute of Medical and Technical sciences, Saveetha University, Chennai, India
Mail id: aravindkumar@saveetha.com

Article Info

Volume 83

Page Number: 2169 - 2297

Publication Issue:

July-August 2020

Article History

Article Received: 06 June 2020

Revised: 29 June 2020

Accepted: 14 July 2020

Publication: 25 July 2020

Abstract

Clinical Photography is an important requirement for better clinical diagnosis, treatment planning and case documentation in modern Orthodontics. The primary purpose of dental photography is clinical recording of intra oral and extra oral manifestations. Other secondary uses may be marketing, education, communication, dento legal documentation. Dental photography also improves the quality of care provided and overall status of a dental practice. Main purpose of dental photography in orthodontics is documentation for explaining and demonstrating various stages and processes involved in a treatment and to assess the treatment progress. Till date there are no existing surveys on dental photography from a patient's perspective. A cross-sectional questionnaire study was conducted among the patients undergoing orthodontic therapy. The sample size of 300 patients were selected. A close ended questionnaire was used to assess the patient perspective about the dental photographs taken during the orthodontic therapy. A survey software was used to reduce sampling bias. Repeated answers or questioning were avoided. All patients undergoing fixed orthodontic treatment were included in the study. Chi-square tests are applied to find the association between the parameters and the level of significance. Patient satisfaction and comfort is of utmost importance. Hence changes in the design can be brought about in retractors or mirrors to improve the comfort of the patient during clinical photography. Within the limits of the study, the result of the study has shown that there was positive experience regarding dental photography for orthodontic purposes from the majority of the patients.

Keywords: Digital photography; documentation; discomforts; orthodontic therapy; patient perspective.

INTRODUCTION

Digital photography today has penetrated into almost all scenes and societies. It is also changing the perceptions in the field of medicine and dentistry. (Bengel, 1984; Moncada *et al.*, 2014)

In dentistry the basic aim of dental photography is documentation. Documentation involves photography of all processes and stages of a procedure. Pre and post operative photographs can be of vital importance in medico legal issues. (Mladenović, Mladenović and Mladenović, 2010)

It may also be used in patient education and motivation. Apart from these considerations, dental photography may also be used in communication in dentists and technician. (Christensen, 2005). It should be also noted that digital photography has revolutionized dental photography where photo can be process almost with no delay whereas conventional techniques which will take days to weeks. (Christensen, 2005) .In orthodontics, both extraoral and intraoral photos are required . The photographic documentation of patients undergoing orthodontic treatment is essential as it aids in the diagnosis, formulating treatment plans, to assess the progress of the treatment, for the purpose of research and publications, for lecture classes and teaching presentations. Digital photos nowadays can be rotated, enlarged, darkened, enhanced, cropped or changed in any way and also be projected into small handheld devices to larger screens. (Christensen, 2005)

Lighting plays a major role in reproducing accurate shades in dental photography. Twin flash and ring flash are commonly used in camera flash. (Bengel, 1985) Gifter *et al* (Çifter, 2018) in his study about dental photography concluded that most patients complained about stress during intra oral photos. intraoral mirrors and retractors were primary causes of patient stress .During the procedure, the mirrors and retractors caused pain for most patients. .Inefficient

designs and lack of compatibility between the items used were the primary reasons for patients complaints. (Çifter, 2018). New instrument designs should be patient-centred to increase comfort and efficiency.

Previously our team had conducted numerous clinical trials (Sivamurthy and Sundari, 2016; Felicita, 2017a, 2018; Samantha *et al.*, 2017), lab studies (Kumar *et al.*, 2011; Dinesh *et al.*, 2013; Kamisetty *et al.*, 2015; Krishnan, Pandian and Kumar S, 2015; Rubika, Sumathi Felicita and Sivambiga, 2015; Viswanath *et al.*, 2015; Felicita, 2017b; Vikram *et al.*, 2017) and other studies (Felicita, Chandrasekar and Shanthasundari, 2012; Jain, Kumar and Manjula, 2014) over the past 5 years. Now we are focussing on epidemiological surveys. The idea for this survey stemmed from the current interest in our community. Hence this survey was conducted to understand a patient's perspective during a regular dental photography procedure while undergoing orthodontic therapy.

MATERIALS AND METHODS

Study design and setting:

The study setting is university based study. A cross sectional study was conducted on 300 patients under fixed appliance therapy who visited Saveetha dental College .Thus the population includes all patients under fixed appliance therapy. The advantage of this study was that the study population belonged to the same ethnic group and also can be used to create awareness among clinicians regarding the field of study .However, the drawback of this study was patient participation, only patients who were ready to cooperate were included in the study. The internal validity of the study was carried out by analysing all patients under fixed appliance therapy. The external validity was homogenization and replication of the experiment.

Data collection

A survey software was used to reduce sampling bias. Repeated answers or questions were avoided. All patients undergoing fixed orthodontic treatment were included in the study. Data collection was done using a self structured questionnaire consisting of 12 questions. Google forms were used to collect the data and circulate among the patients. Variables such as gender and age were also collected. Data was assessed based on these variables. File charts were used to represent each variable. Questions were based on patient experience, opinion and whether it is useful. Data analysis done using SPSS by IBM.

Statistical Analysis

After tabulation using MS Excel, the data was exported to IBM SPSS software [Version 19: IBM Corporation NY USA] for statistical analysis. Descriptive statistics was done to assess the responses given by the patients. The dependent variable was all the patients undergoing fixed appliance therapy. The independent variable was age and gender.

Ethical Approval

The ethical approval for the retrospective study was obtained from the institutional ethics board.

RESULTS AND DISCUSSION

A total Of 300 patients who underwent orthodontic therapy were involved in the study. Out of which majority (Figure1)of the patients involved in the study were females(56%) compared to males(44%).Figure 2 shows that the majority of the patients belonged to the age group of 10-20 years(45.33%) followed by patients in the 20-30 (33.33%)age group and 30-40(23.33%) age group. Among the patients 70.33% responded that photos were necessary for treatment in orthodontics and only the remaining 29.67% felt otherwise (Figure 3). Majority of patients gave consent (90.67%) before

proceeding with dental photography followed by patients(Figure 4) who responded that consent was not taken prior to photography (9.33%). Majority(55.67%)of the patients confirmed that they were comfortable during the entire process of photography(Figure 5). Among the responses 82.67% of the patients responded that intra oral photos were more uncomfortable than extra oral photos (Figure 6) and Figure 7 shows that the 79.77% of the patients felt photos taken of the mandibular arch were more uncomfortable than maxillary arch.Among the respondents 31.7% of the patients(Figure 8) strongly confirmed that occlusal mirrors were most uncomfortable as compared to cheek retractors(26.33%),tongue retractors(18.67%) and camera flash(24%). Majority (Figure 9)of the patients (96.33%) claimed that they appreciate changes in alignment of teeth from photographs. Among The Total respondents,(Figure10) majority (71.6%) of the patients agreed to use their photos for advertisements or for educational purposes. Majority (39.67%) of the patients felt retraction was a parameter that needed to be improved to reduce the discomfort(Figure 11). Among the respondents,79.33% of the study population claimed to have a good overall experience during dental photography.(Figure 12).

Gender distribution among age groups shows that the majority (25.67%) of the patients were females belonging to the 10-20 years of age group and figure 14 shows majority 51.67% of the female patients have responded that consent was obtained before taking photographs for treatment. 43.67% of the female patients (Figure 15) were of the opinion that dental photography was necessary in orthodontic treatment Pearson Chi square value -0.001(<0.05) hence, statistically significant .Figure 16 shows majority 28.67% of female patients have responded that they were uncomfortable with the photographs being taken during the treatment.Chi square test, p value-0.00 (<.05) hence statistically significant. Among the

respondents(Figure 17) 49.67% of the female patients are of the opinion that intra oral photography was uncomfortable compared to extra oral photography during orthodontic treatment. Pearson Chi square test,p value -0.002(<0.05) hence, statistically significant . On analysing the association between the gender and arch(Figure 18), the majority of the female patients(47%) were of the opinion that the mandibular arch was the most uncomfortable compared to maxillary arch when being photographed during orthodontic treatment. Figure 19 shows a majority 17.67% of female patients to have responded that occlusal mirrors were the most uncomfortable material compared to retractors and flash of the camera and Figure 20 shows 53.67% of the female patients to be of the opinion that they could appreciate the outcome of the treatment from pre treatment and post treatment photographs taken during orthodontic treatment. Pearson Chi square test,p value -0.603(>0.05) hence, statistically not significant . On analysing the association between gender and the consent to use the photographs for advertisements and educational purposes(Figure 21) majority (48.33%) of female patients gave consent to use their photographs to be used for advertisements or educational purposes .Chi square test, p value-0.00 (<0.05) hence statistically significant.Among the respondents (Figure 22) ,67% of the female patients are of the opinion that retractors used during photography was the major parameter that needed to be improved to reduce the discomfort.Onanalysing the association between the gender and overall experience,(Figure 23) majority 45% of the female patients have responded that they had a overall good experience during the process of photography while undergoing treatment.Pearson Chi square test,p value -0.621(>0.05) hence, statistically not significant .

From the results of study we can conclude that most patients had a positive experience and felt dental photography was an essential part of orthodontics .

During dental photography various equipment were used such as suction, retractors or mirrors At times, multiple items may be used together. Patients had varied opinions regarding the usage of this. Most patients complained of retractors and mirrors.These instruments can not be avoided as full face intraoral smile with full visibility and occlusal photos are vital for documentation.(Moncada *et al.*, 2014; Çifter, 2018)Digital dental photography in orthodontics can help to reassess any errors in band and archwire placement and construction. Photographs may be attached along with case sheets to improve the quality of the data recorded. In some cases, Intra oral photos maybe used to establish inter arch relations thereby reducing the need for dental casts which can be of great importance in certain cases where impression making is a hindrance.(Ahmad, 2009) Clinical photographs also play a major role in medicolegal issues.Measurements from photos can be made for implant planning or any other surgical procedure. Preoperative photographs can be used for shade and site selection during surgical procedures. Teledentistry is an upcoming field of interest in which information and medical records can be exchanged to remote areas where medical or dental care cannot be easily accessed.Similar programs have also been implemented in india to transfer and provide remote dental and medical care. However, digital images can be easily manipulated , changed or edited to produce fake restorations, crowns and other pathologies.(Ahmad, 2009) It is seen that such manipulation of digital images are very difficult to detect and correct, hence, a cautious approach has to be adopted towards digital dental photography. Patients also mentioned the effects of flash. Ring flash caused lacrimation, irritation and discomfort. As in most cases, the distance between flash and the patients is around 20-25cm, it may lead to unfavourable effects of bright light on the eye. Patients also felt that smiling on command was challenging(Çifter, 2018)

Most previous literature agreed with consensus that patients had a positive attitude and retraction was a major area of concern.(Sharland *et al.*, 2004; Desai and Bumb, 2013) From the current study it is evident that all types of retractors except tongue retractors were areas of concern.38% of patients belonging to the age group of 18-55 and 30% of patients belonging to the age group of 31-55% were ready to allow their photos to be used for advertisements and for educational purposes.

No significant literature opposing the consensus was found. Apart from the documentation dental photographs can be used in legal issues, patient doctors and technician communication, Publishing, education and also in dentist marketing. The Survey being conducted within an institution does not represent all ethnic groups and populations. Hence the study can not be generalized. Also subjective errors bias may creep in. Hence a study including all out patients in a similar study setup can provide better accurate results.

Patients must be informed in advance and in detail about the procedure and the equipment to be used. Improved designs for the camera flash system and the intraoral equipment are needed to maximize both patient satisfaction and image quality. Patient comfort is important during the procedure.The designs of the retractors and mirrors must be appealing for patients, and must also be designed to fit or adapt to as many patients as possible.Sharp edges on equipment should be avoided.Different apparatuses must be designed to be compatible and facilitate positioning without needing to be held in place.To protect the patient's eyes from the flash burst, special glasses can be used.

CONCLUSION

Within the limits of the study, the result of the study has shown that there was overall positive experience among the patients regarding dental photography for orthodontic purposes. The most important practice to

be focused during dental photography is to reduce patient complaints and to improve patient comfort. Hence changes in the design can be brought about in retractors or mirrors and by effective management of time during photography.

AUTHOR CONTRIBUTIONS

First author, Suhas Manoharan performed the data collection by reviewing patient details, filtering required data, analysing and interpreting statistics and contributed to manuscript writing.

Second author, Dr. Remmiya Mary Varghese contributed to conception of study title, study design,analysed the collected data, statistics and interpretation and also critically revised the manuscript.

Third author, Dr.AravindKumar.S revised the manuscript. All the three authors have discussed the results and contributed to the final manuscript.

ACKNOWLEDGEMENTS

The authors sincerely thanked Saveetha Dental College and Hospitals, Saveetha Institutes of Medical and Technical Sciences, Saveetha University, Chennai for all the support throughout the study.

CONFLICT OF INTEREST

There were no potential conflicts of interest as declared by authors.

REFERENCES

1. Ahmad, I. (2009) 'Digital dental photography. Part 2: Purposes and uses', British dental journal, 206(9), pp. 459–464.
2. Bengel, W. (1984) Die photographie in Zahnmedizin und Zahntechnik. Quintessenz.

3. Bengel, W. (1985) 'Standardization in dental photography', International dental journal. europepmc.org, 35(3), pp. 210–217.
4. Christensen, G. J. (2005) 'Important clinical uses for digital photography', Journal of the American Dental Association , 136(1), pp. 77–79.
5. Çifter, M. (2018) 'A Qualitative Analysis of Dental Photography in Orthodontics: The Patient's Perspective', BioMed research international. hindawi.com, 2018, p. 5418592.
6. Desai, V. and Bumb, D. (2013) 'Digital dental photography: a contemporary revolution', International journal of clinical pediatric dentistry. ncbi.nlm.nih.gov, 6(3), pp. 193–196.
7. Dinesh, S. P. S. et al. (2013) 'An indigenously designed apparatus for measuring orthodontic force', Journal of clinical and diagnostic research: JCDR, 7(11), pp. 2623–2626.
8. Felicita, A. S. (2017a) 'Orthodontic management of a dilacerated central incisor and partially impacted canine with unilateral extraction--A case report', The Saudi dental journal. Elsevier, 29(4), pp. 185–193.
9. Felicita, A. S. (2017b) 'Quantification of intrusive/retraction force and moment generated during en-masse retraction of maxillary anterior teeth using mini-implants: A conceptual approach', Dental press journal of orthodontics. SciELOBrasil, 22(5), pp. 47–55.
10. Felicita, A. S. (2018) 'Orthodontic extrusion of Ellis Class VIII fracture of maxillary lateral incisor--The sling shot method', The Saudi dental journal. Elsevier, 30(3), pp. 265–269.
11. Felicita, A. S., Chandrasekar, S. and Shanthasundari, K. K. (2012) 'Determination of craniofacial relation among the subethnic Indian population: a modified approach - (Sagittal relation)', Indian journal of dental research: official publication of Indian Society for Dental Research. ijdr.in, 23(3), pp. 305–312.
12. Jain, R. K., Kumar, S. P. and Manjula, W. S. (2014) 'Comparison of intrusion effects on maxillary incisors among mini implant anchorage, j-hook headgear and utility arch', Journal of clinical and diagnostic research: JCDR. ncbi.nlm.nih.gov, 8(7), pp. ZC21–4.
13. Kamisetty, S. K. et al. (2015) 'SBS vs Inhouse Recycling Methods-An Invitro Evaluation', Journal of clinical and diagnostic research: JCDR. ncbi.nlm.nih.gov, 9(9), pp. ZC04–8.
14. Krishnan, S., Pandian, S. and Kumar S, A. (2015) 'Effect of bisphosphonates on orthodontic tooth movement-an update', Journal of clinical and diagnostic research: JCDR. ncbi.nlm.nih.gov, 9(4), pp. ZE01–5.
15. Kumar, K. R. R. et al. (2011) 'Depth of resin penetration into enamel with 3 types of enamel conditioning methods: A confocal microscopic study', American Journal of Orthodontics and Dentofacial Orthopedics, pp. 479–485. doi: 10.1016/j.ajodo.2010.10.022.
16. Mladenović, D., Mladenović, L. and Mladenović, S. (2010) 'Importance of digital dental photography in the practice of dentistry', Acta Facultatis Medicae Naissensis. publisher.medfak.ni.ac.rs, 27(2). Available at: http://publisher.medfak.ni.ac.rs/AFMN_1/2010/2-2010/4%20Dragan%20Mladenovic.pdf.
17. Moncada, G. et al. (2014) 'Evaluation of dental restorations: a comparative study between clinical and digital photographic assessments', Operative dentistry. jopdentonline.org, 39(2), pp. E45–56.
18. Rubika, J., Sumathi Felicita, A. and Sivambiga, V. (2015) 'Gonial Angle as an Indicator for the Prediction of Growth Pattern', World Journal of Dentistry, pp. 161–163. doi: 10.5005/jp-journals-10015-1334.
19. Samantha, C. et al. (2017) 'Comparative Evaluation of Two Bis-GMA Based

- Orthodontic Bonding Adhesives - A Randomized Clinical Trial', Journal of clinical and diagnostic research: JCDR. ncbi.nlm.nih.gov, 11(4), pp. ZC40–ZC44.
20. Sharland, M. R. et al. (2004) 'Use of dental photography by general dental practitioners in Great Britain', Dental update. magonlinelibrary.com, 31(4), pp. 199–202.
21. Sivamurthy, G. and Sundari, S. (2016) 'Stress distribution patterns at mini-implant site during retraction and intrusion—a three-dimensional finite element study', Progress in orthodontics. Springer, 17(1), p. 4.
22. Vikram, N. R. et al. (2017) 'Ball Headed Mini Implant', Journal of clinical and diagnostic research: JCDR. ncbi.nlm.nih.gov, 11(1), pp. ZL02–ZL03.
23. Viswanath, A. et al. (2015) 'Obstructive sleep apnea: awakening the hidden truth', Nigerian journal of clinical practice, 18(1), pp. 1–7.

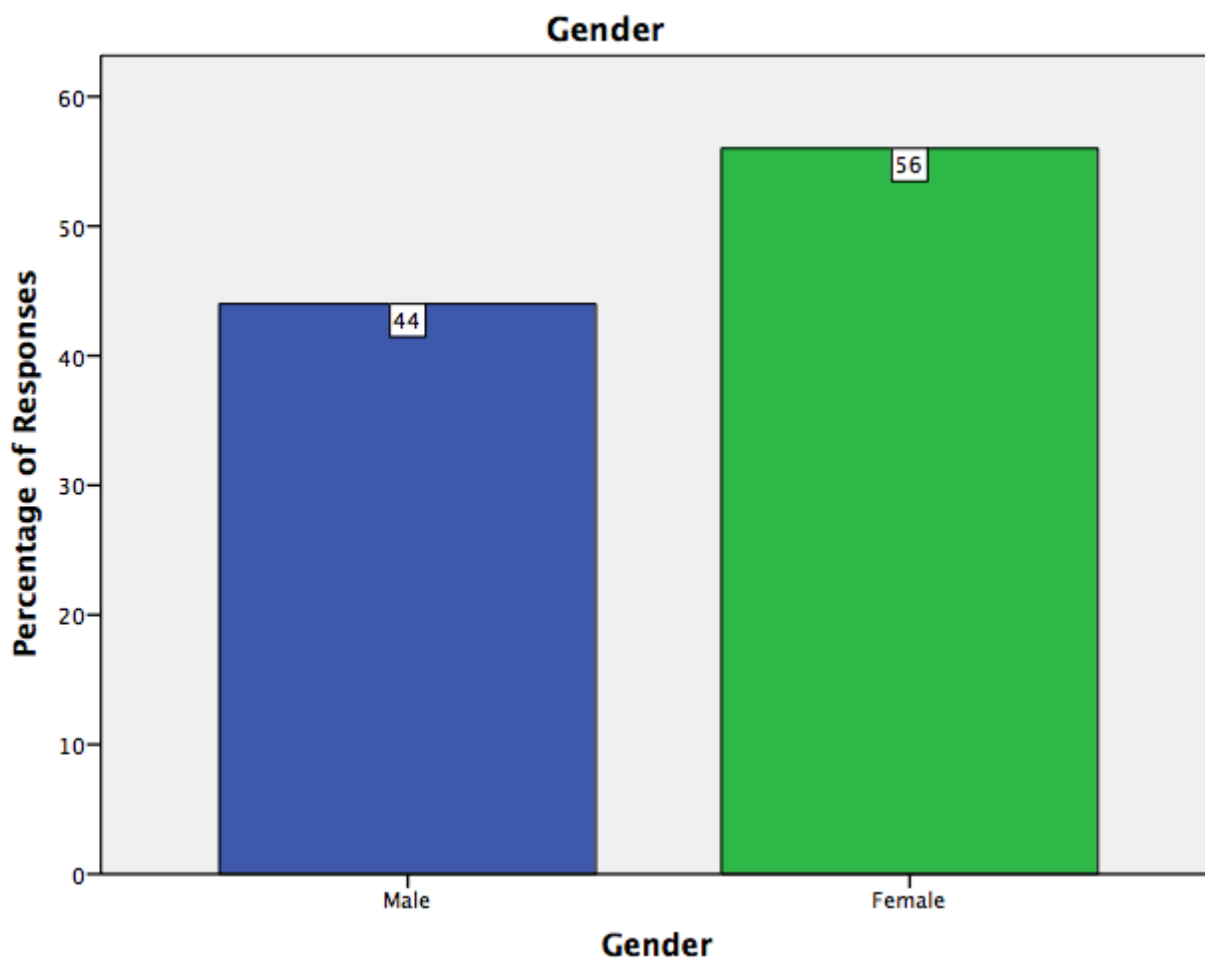


Figure 1: Bar graph showing the distribution of patients included in the study undergoing fixed appliance therapy based on their gender. X axis depicts the gender of patients. Y axis represents the percentage of patients under fixed appliance therapy who were photographed. The graph shows that the majority of the patients were females compared to males.

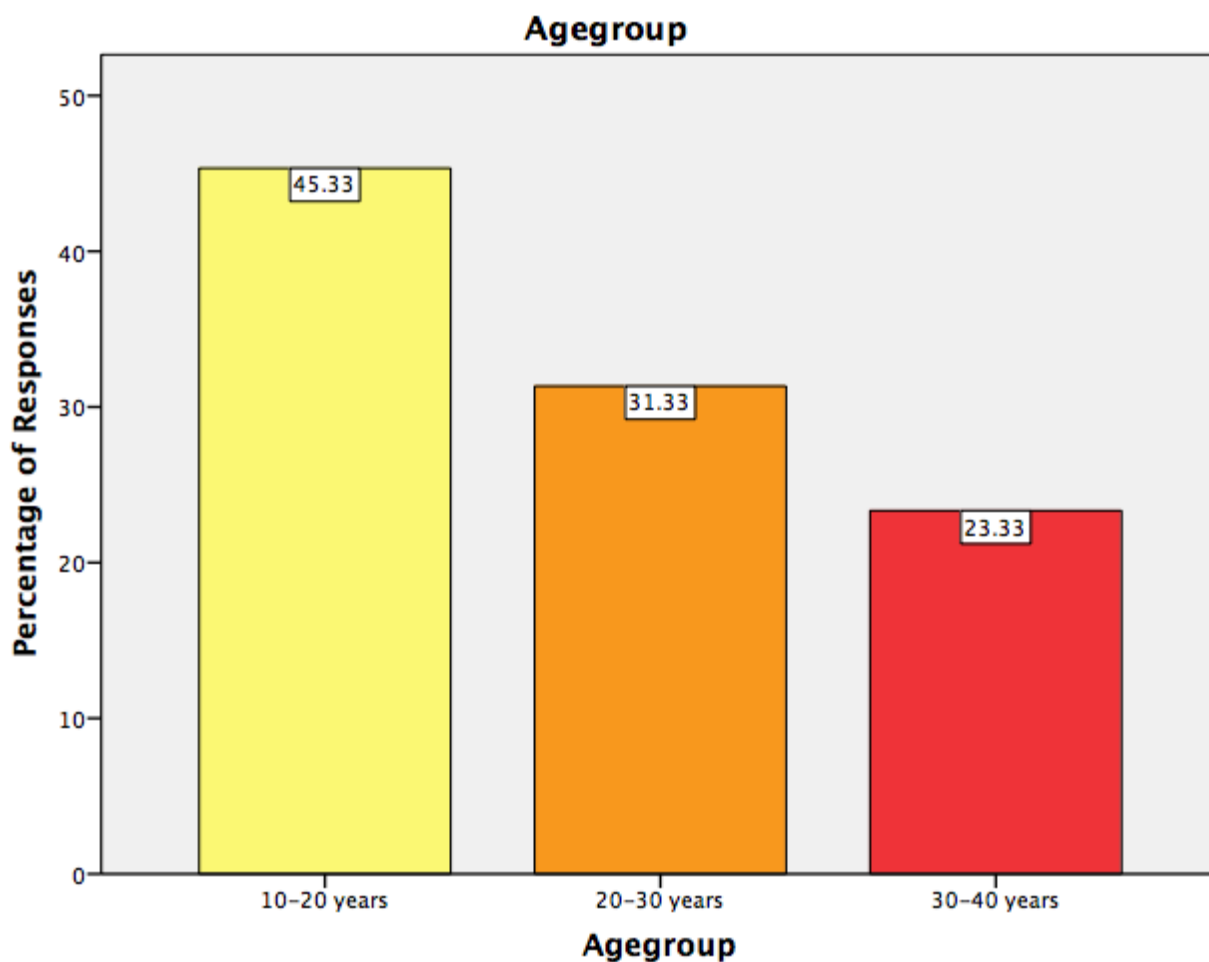


Figure 2: Bar graph shows the distribution of patients included in the study undergoing fixed appliance therapy based on their age. X - axis depicts the age group of patients. Y axis represents the patients under fixed appliance therapy. The graph shows that the majority of the patients belonged to the age group of 10-20 years followed by patients in the 20-30 age group and 30-40 age group .

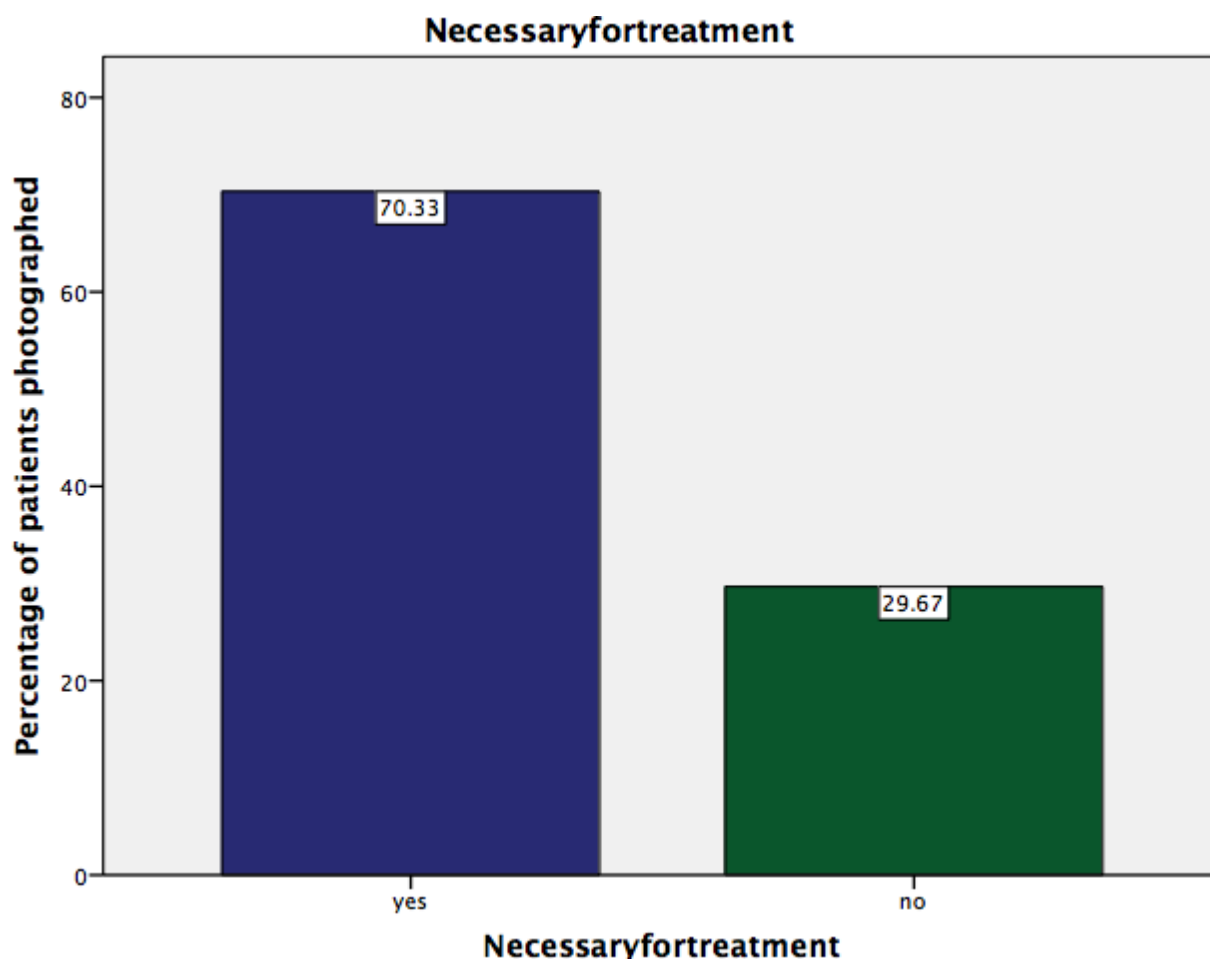


Figure 3: Bar graph representing the responses for the question, whether dental photography was necessary for treatment from a patient's perspective. X-axis represents the response options, Y-axis represents the percentage of responses. The graph shows that the majority of the patients thought that photos were necessary for treatment in orthodontics.

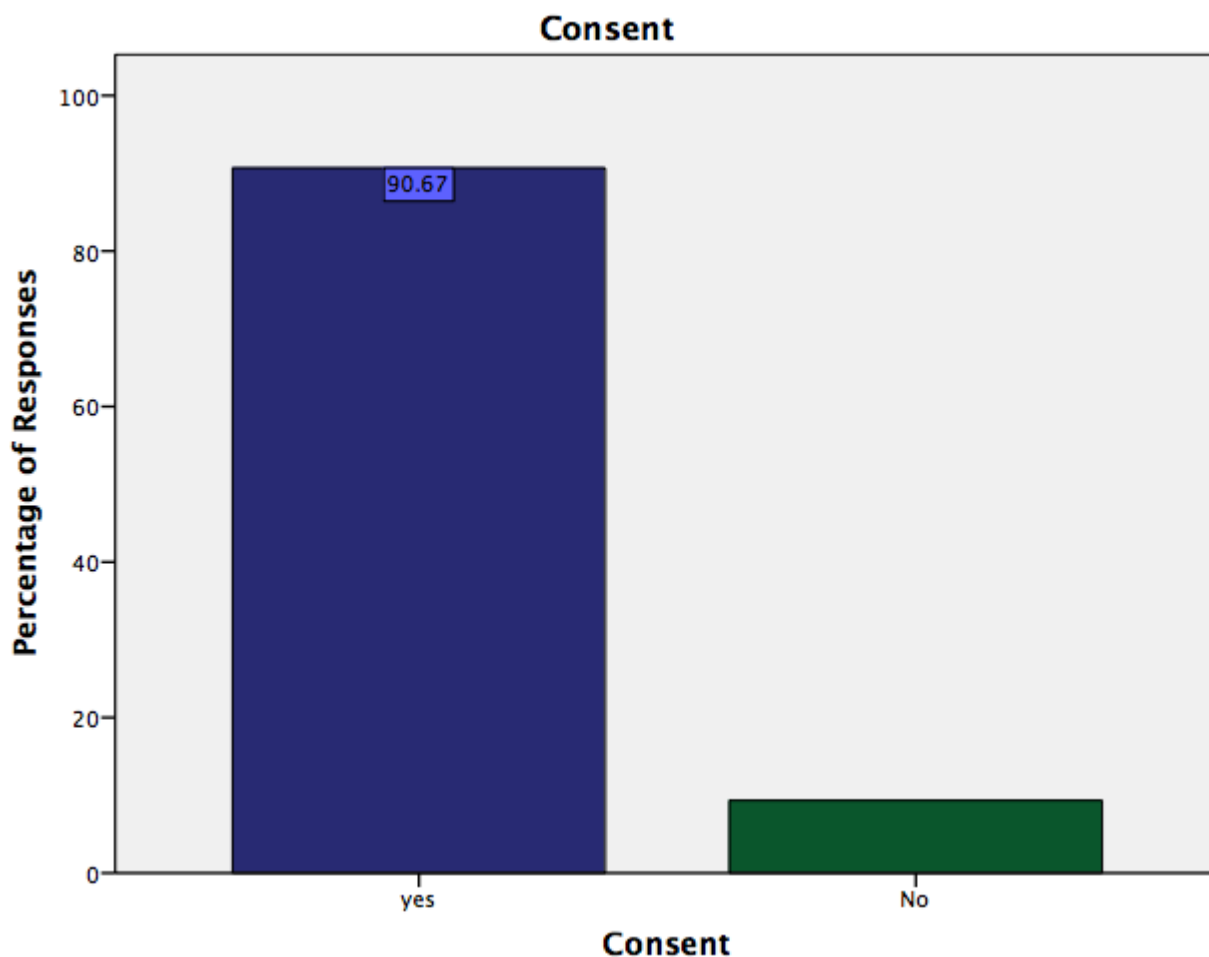


Figure 4: Bar graph representing the responses for the question, whether necessary consent was taken before dental photography. X a-axis represents the response options, Y-axis represents the percentage of responses. The graph shows that a majority of patients gave consent before proceeding with dental photography followed by patients who responded that consent was not taken prior to photography.

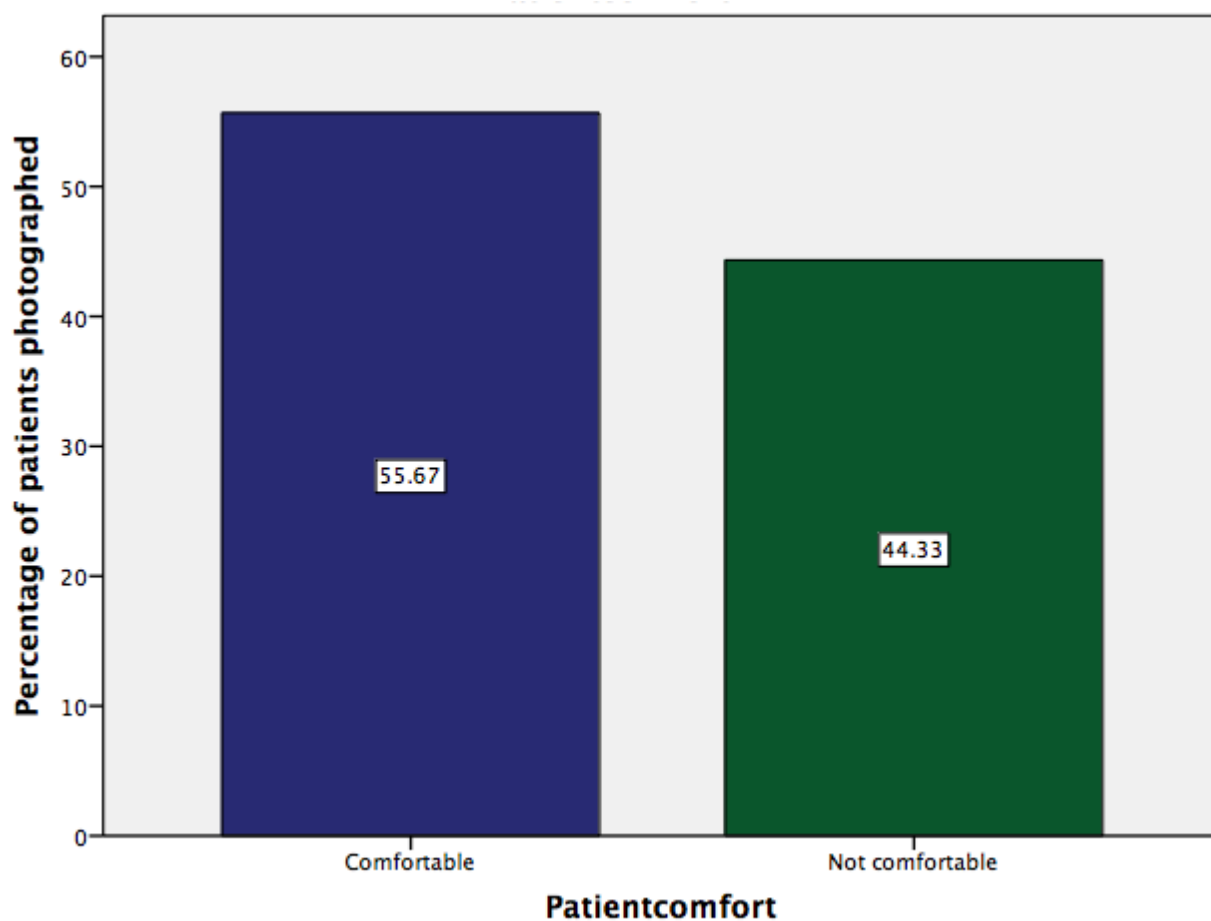


Figure 5: Bar graph representing the responses for the question, whether the patient was comfortable during dental photography for orthodontic treatment. X a-axis represents the response options, Y-axis represents the percentage of responses. From this graph it can be inferred that the majority of the patients were comfortable during the entire process of photography.

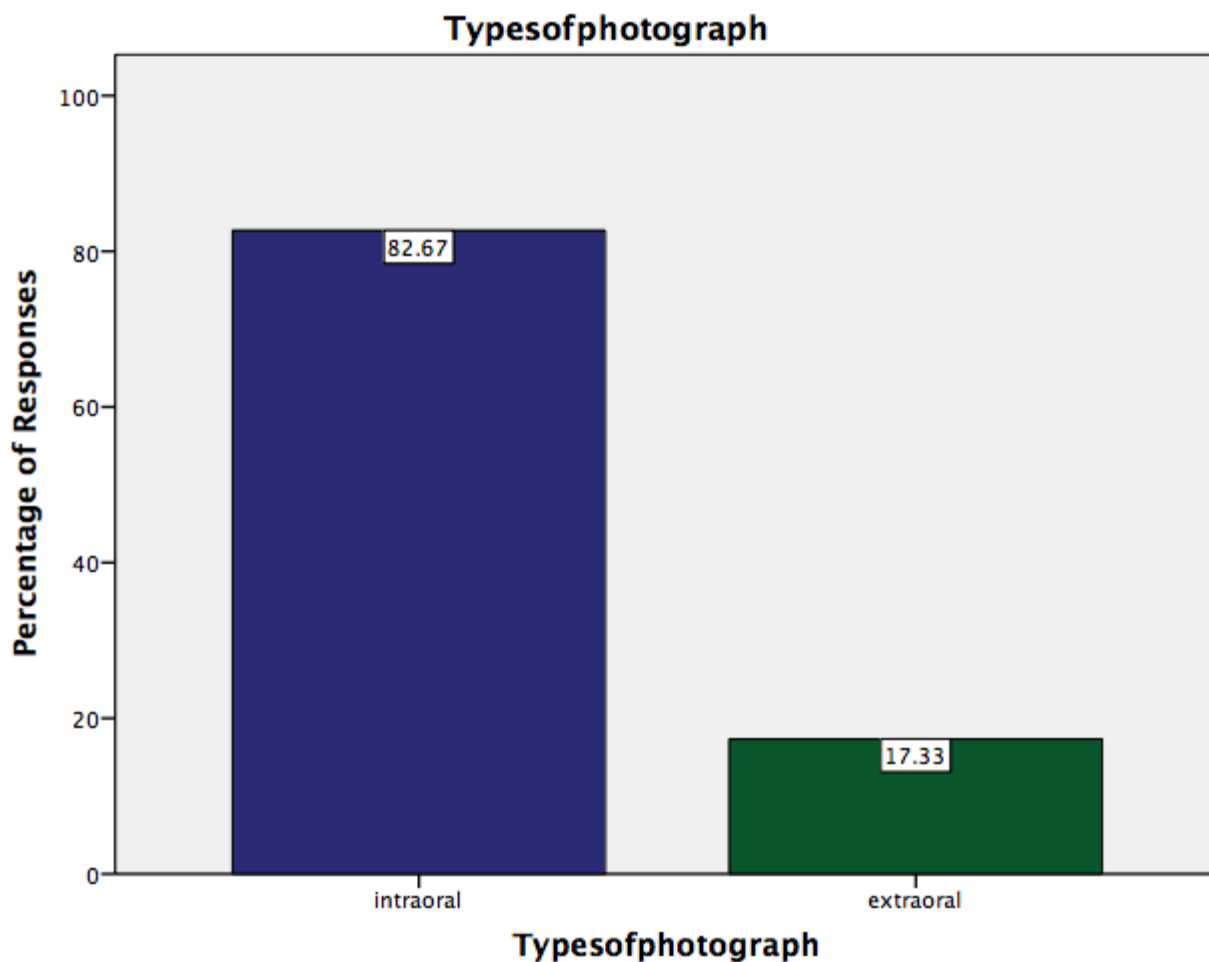


Figure 6: Bar graph representing the responses for the question, which type of photography was not comfortable. X a-axis represents the response options, Y-axis represents the percentage of responses. The graph shows that the majority of the patients felt intra oral photos were more uncomfortable than extra oral photos.

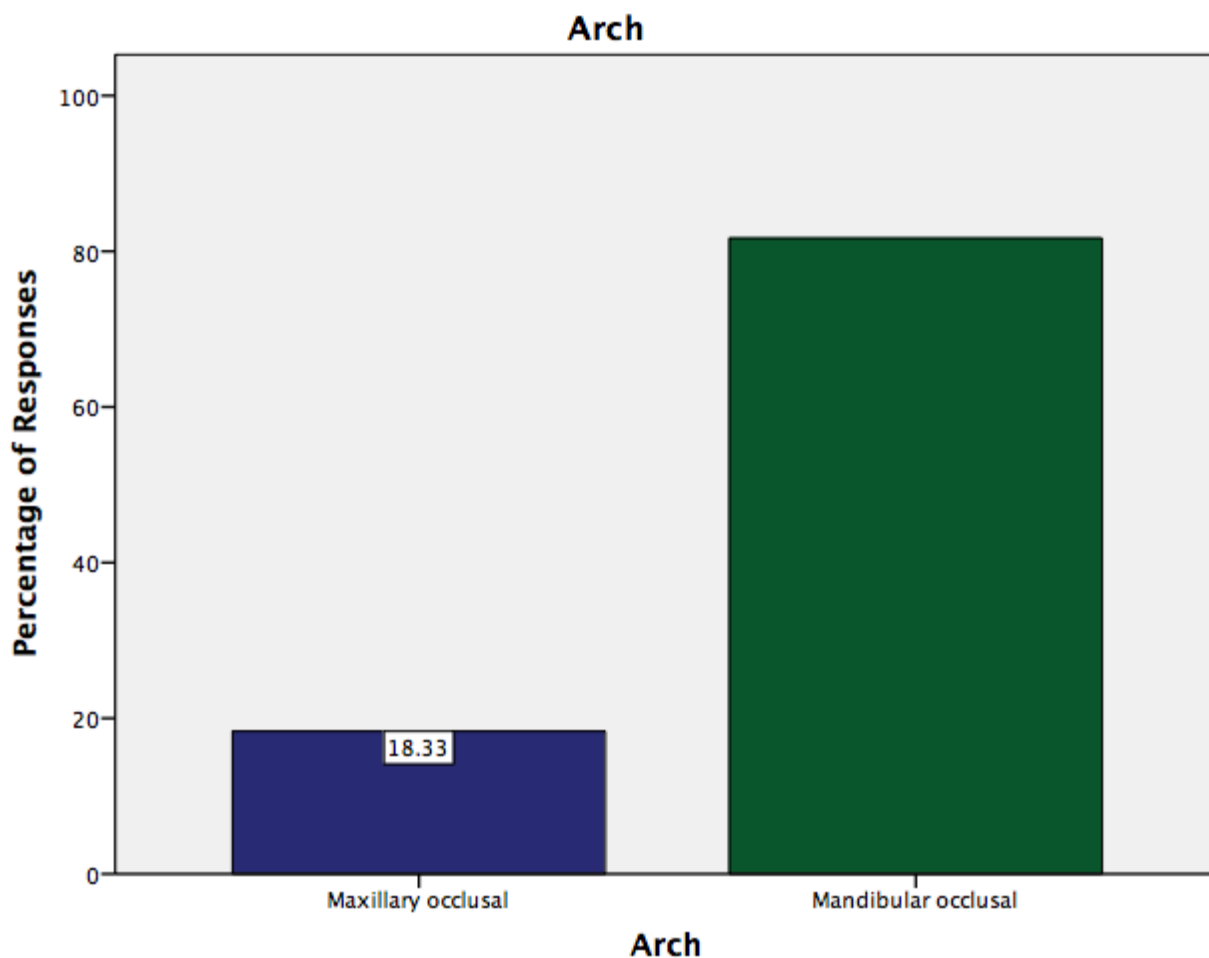


Figure 7: Bar graph representing the responses for the question, which arch was uncomfortable for the patient during photography. X a-axis represents the response options, Y-axis represents the percentage of responses. The graph shows that the majority of the patients felt photos taken of the mandibular arch were more uncomfortable than maxillary arch.

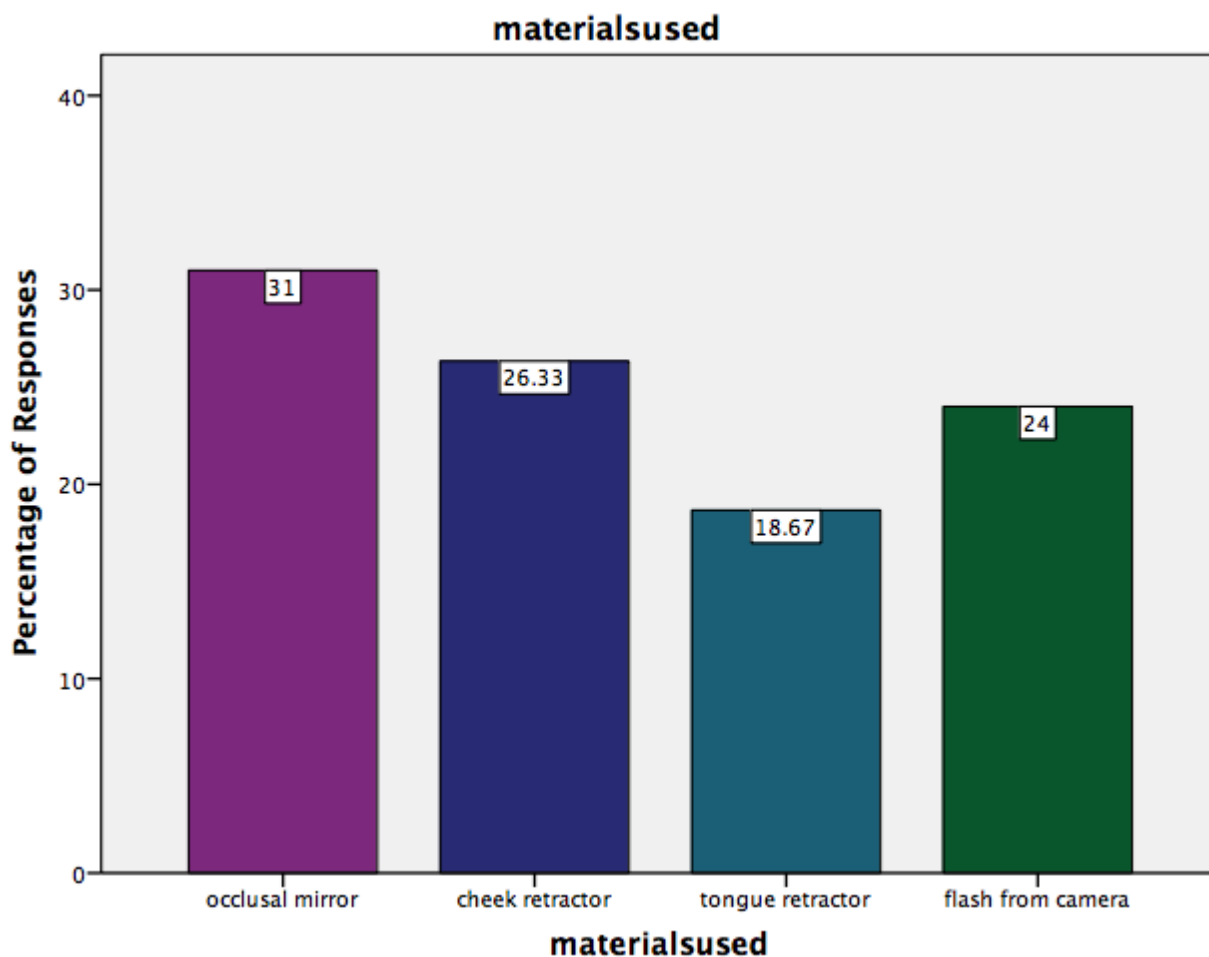


Figure 8: Bar graph representing the responses for the question, which instrument used in dental photography was of most discomfort . X a-axis represents the response options, Y-axis represents the percentage of responses. The graph shows that the majority of the patients felt occlusal mirrors were most uncomfortable as compared to cheek retractors, tongue retractors and camera flash.

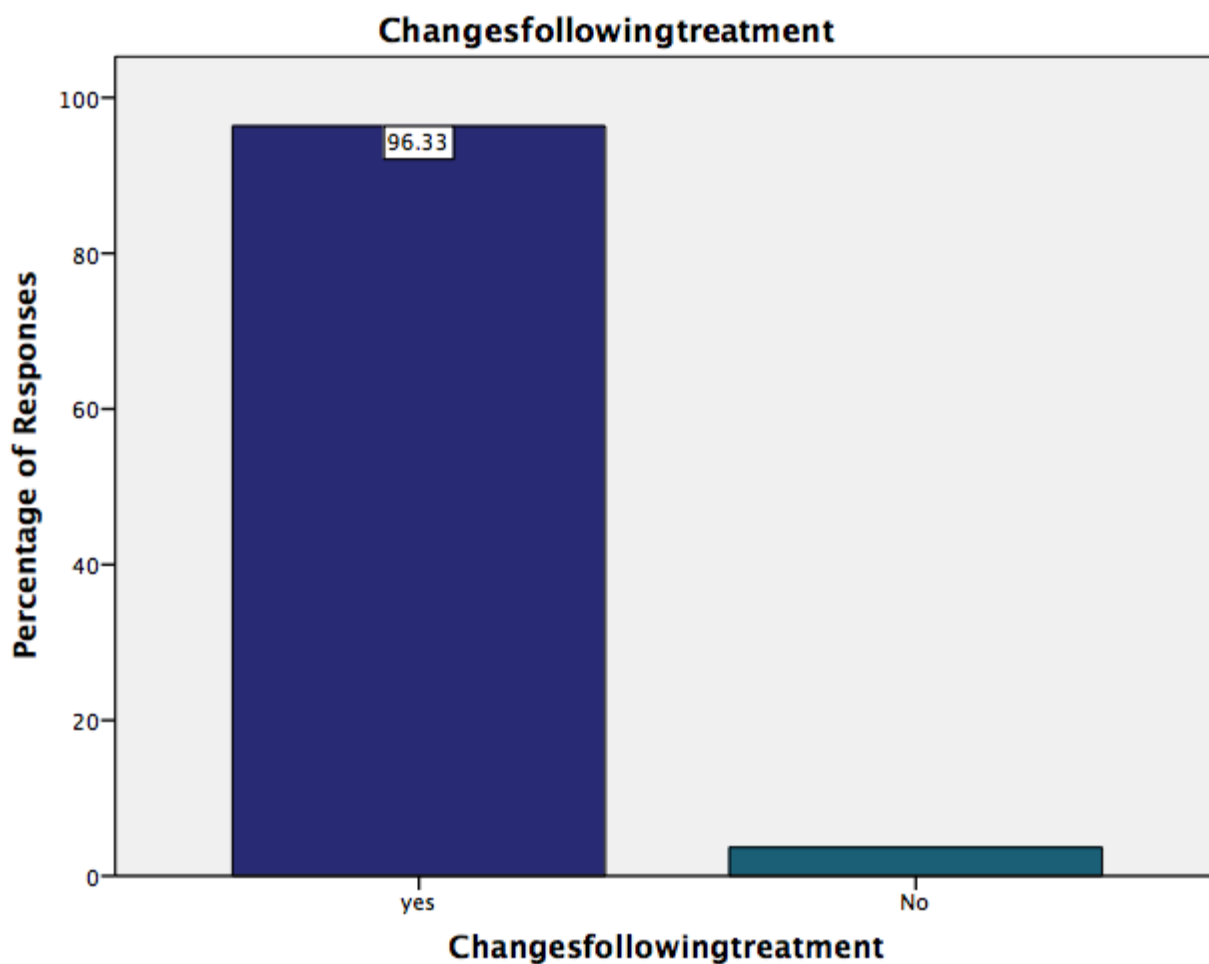


Figure 9: Bar graph representing the responses for the question, whether the patients could appreciate changes post orthodontic treatment from photographs.. X a-axis represents the response options, Y-axis represents the percentage of responses. The graph shows that the majority of the patients claimed that they appreciate changes in alignment of teeth from photographs.

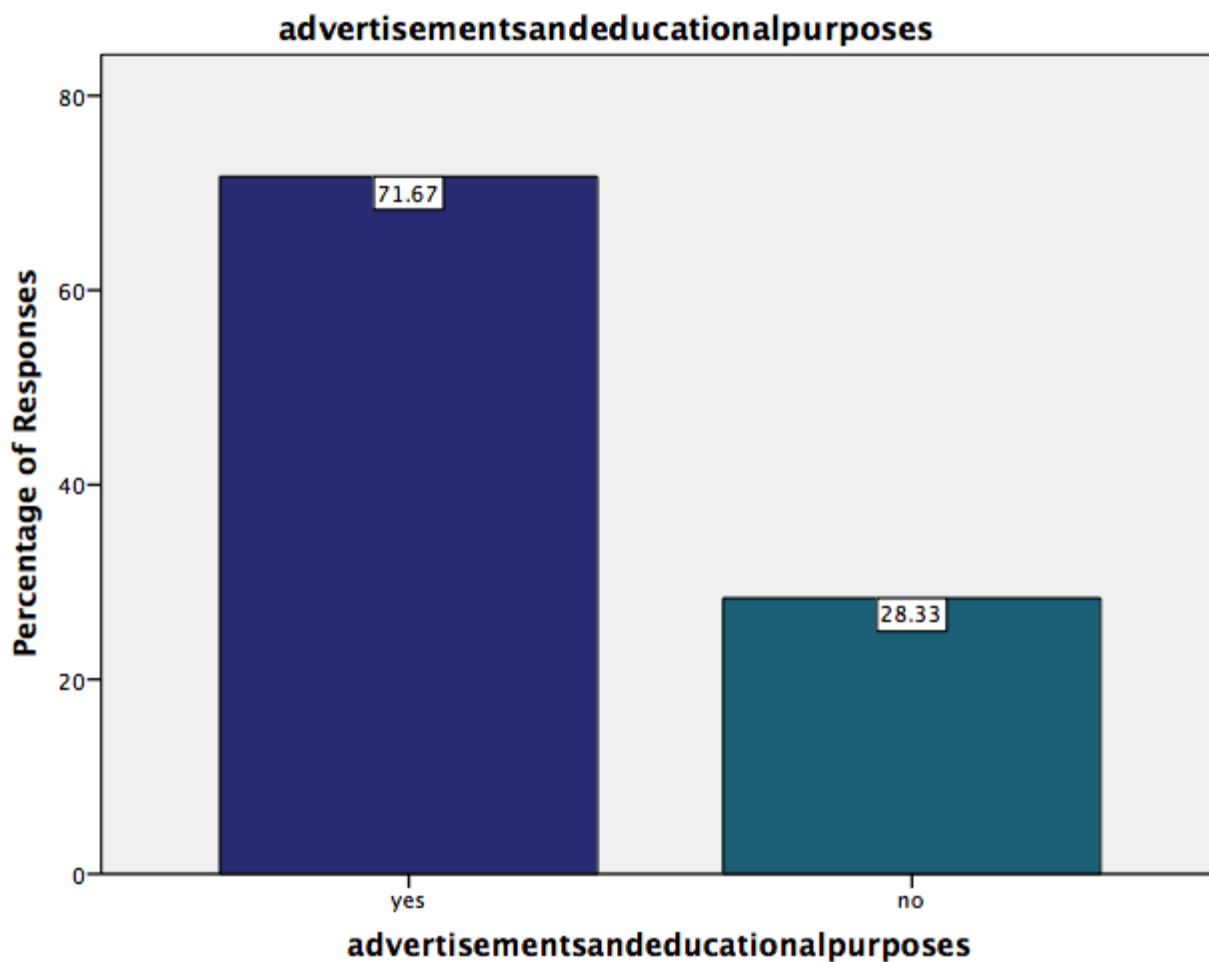


Figure 10: Bar graph representing the responses for the question, if the photos taken can be used for advertisement or educational purposes. X a-axis represents the response options, Y-axis represents the percentage of responses. The graph shows that the majority of the patients agreed to use their photos for advertisements or for educational purposes.

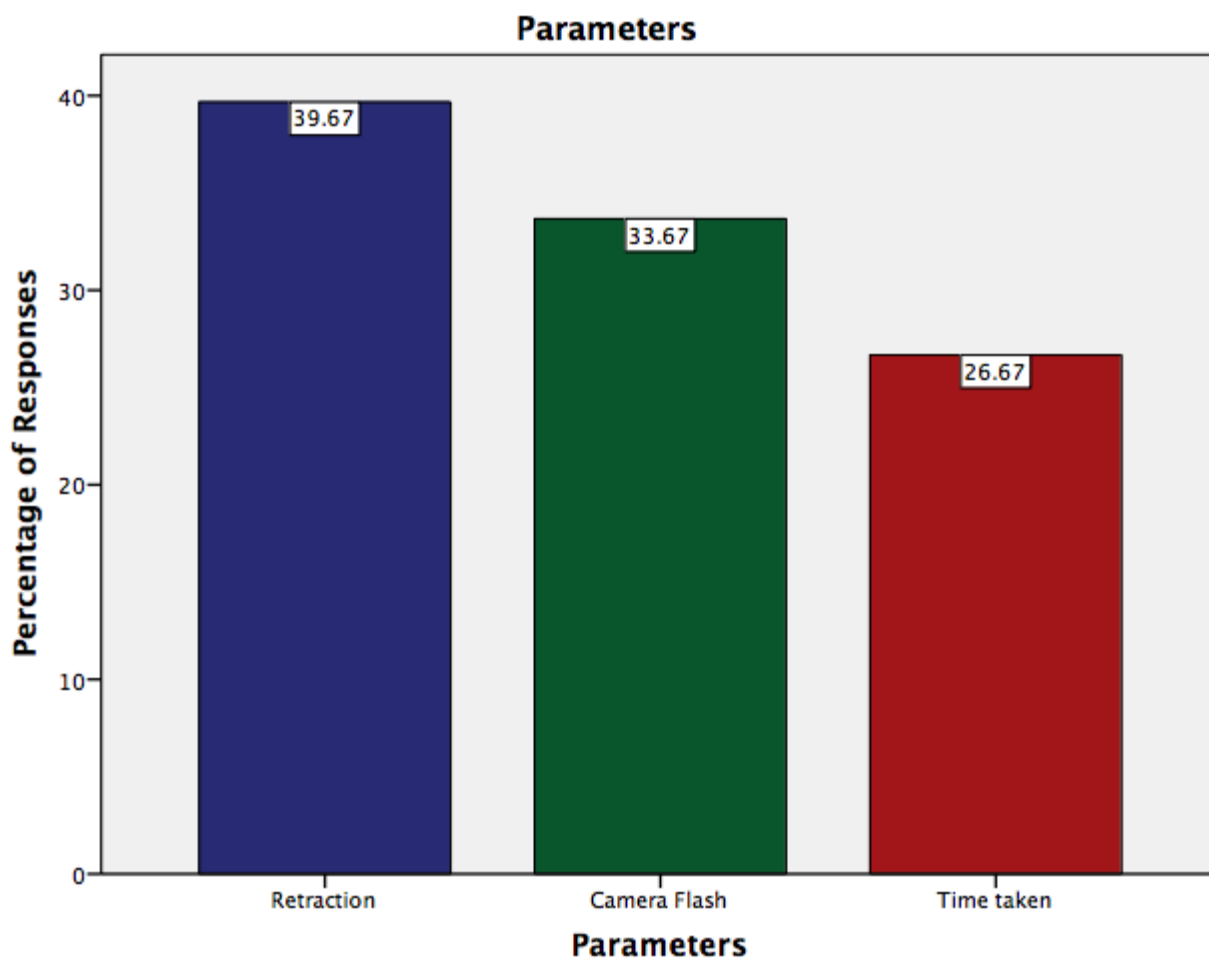


Figure 11: Bar graph representing the responses for the question, which parameters need to be improved for better comfort during photography. X-axis represents the response options, Y-axis represents the percentage of responses. The graph shows that the majority of the patients felt retraction was a parameter that needed to be improved to reduce the discomfort.

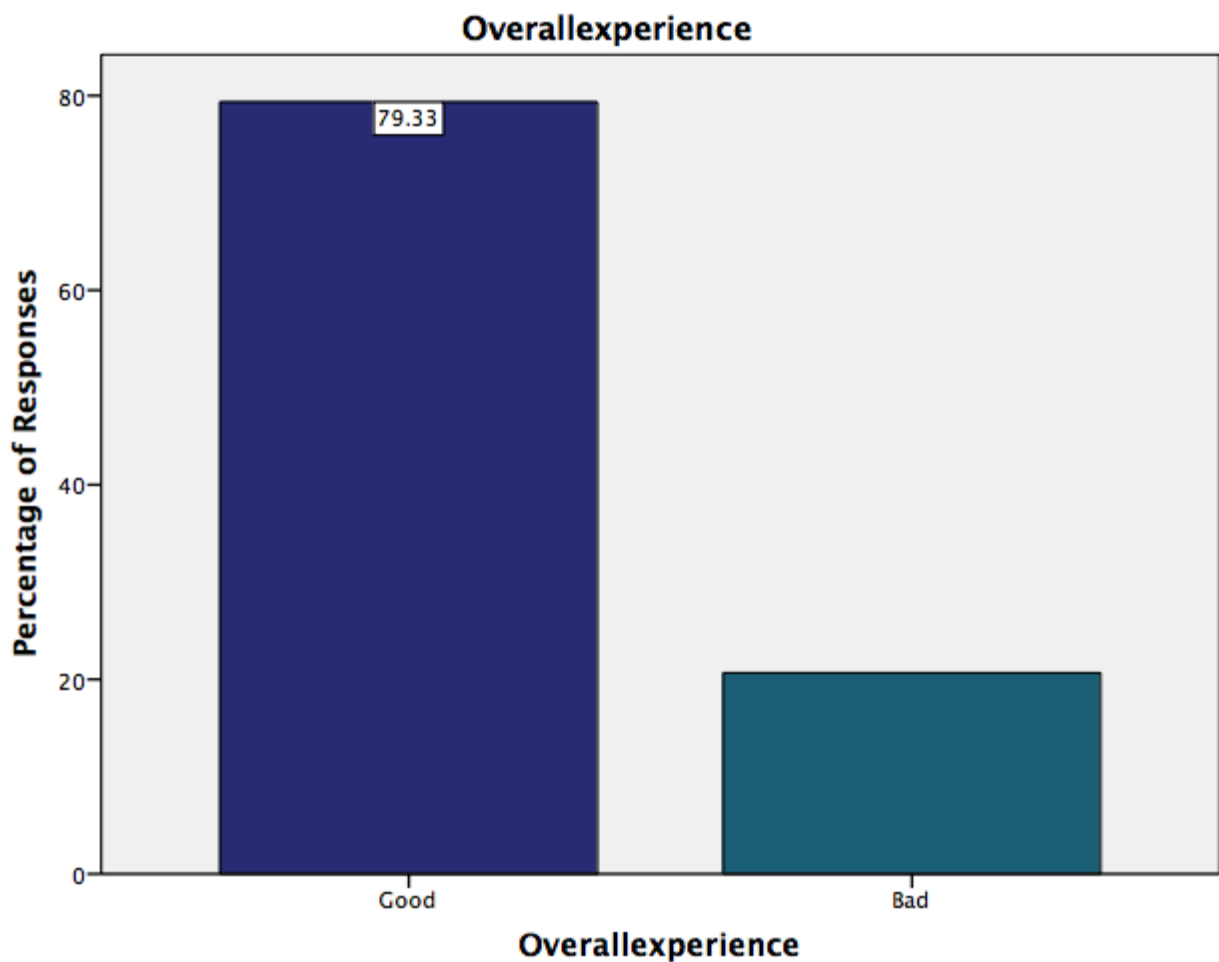


Figure 12: Bar graph representing the responses for the question, regarding patients overall experience about the photographs taken during treatment. X-axis represents the response options, Y-axis represents the percentage of responses. The graph shows that the majority of the patients had a good overall experience.

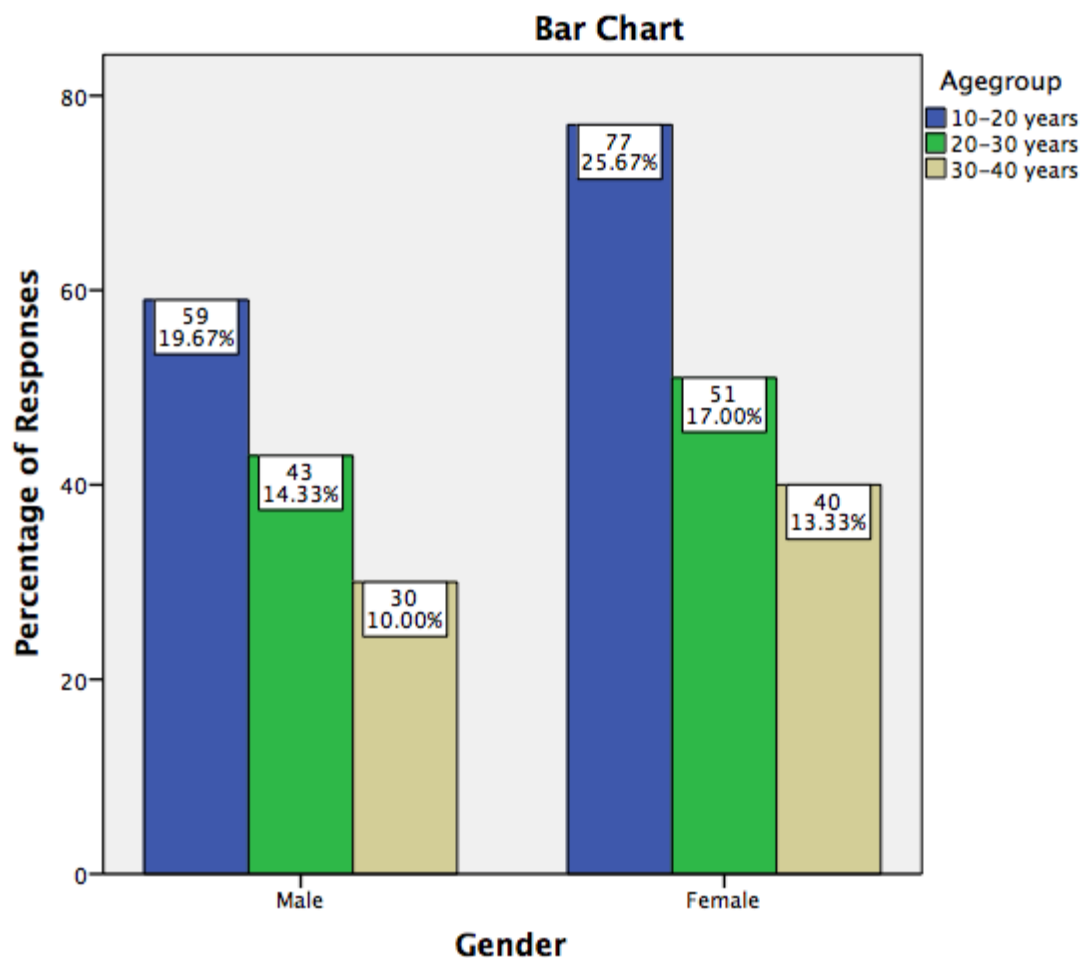


Figure 13: Bar graph shows the association between gender and age of the study population. X axis depicts the gender of the patient. Y axis represents the patients undergoing fixed appliance therapy. The graph shows that the majority of the patients were females belonging to 10-20 years of age group. Chi square test was done. p value-0.917(<0.05), hence statistically not significant.

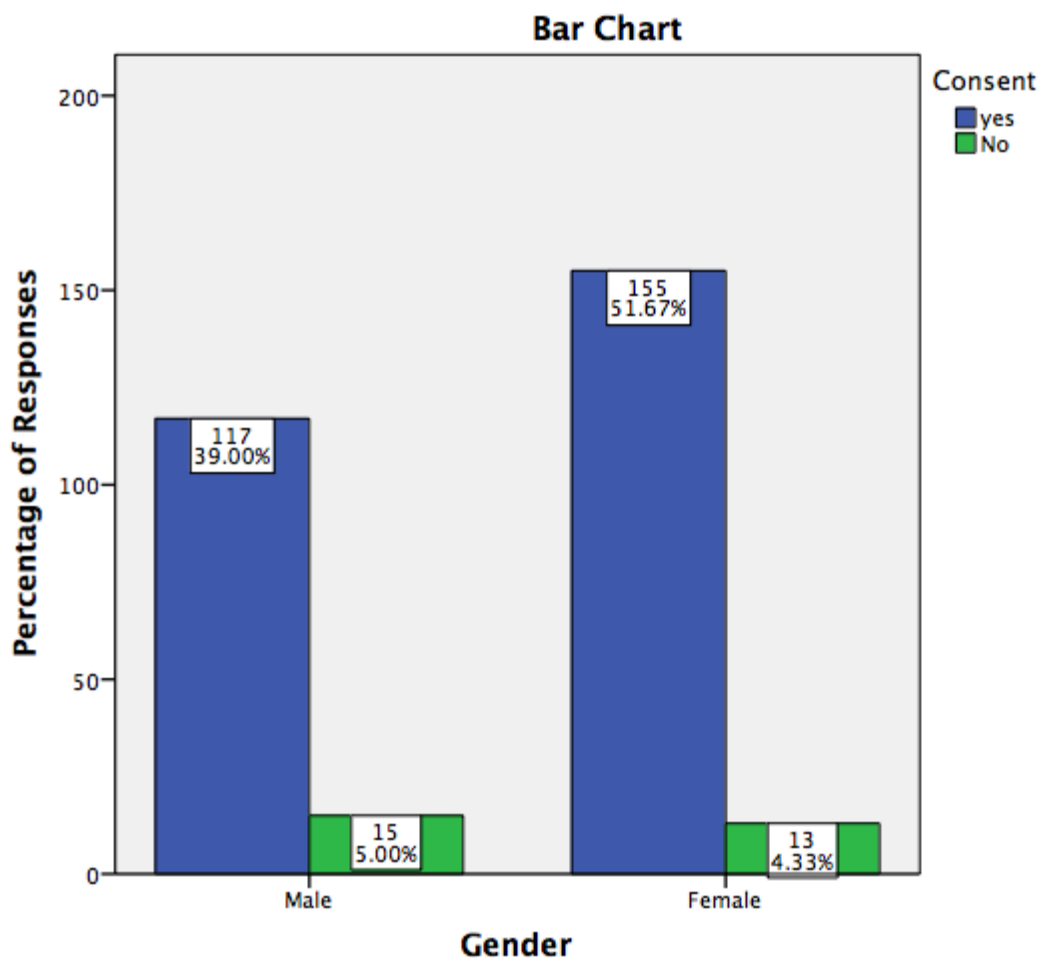


Figure 14: Bar graph depicts the gender distribution of different responses obtained regarding the consent obtained from patients before taking photographs for the treatment. X axis denotes the gender of the patient. Y axis denotes the number of patients. (Chi square test, pvalue-0.284 (>0.05) hence statistically not significant.

Majority of the female patients have responded that consent was obtained before taking photographs for treatment.

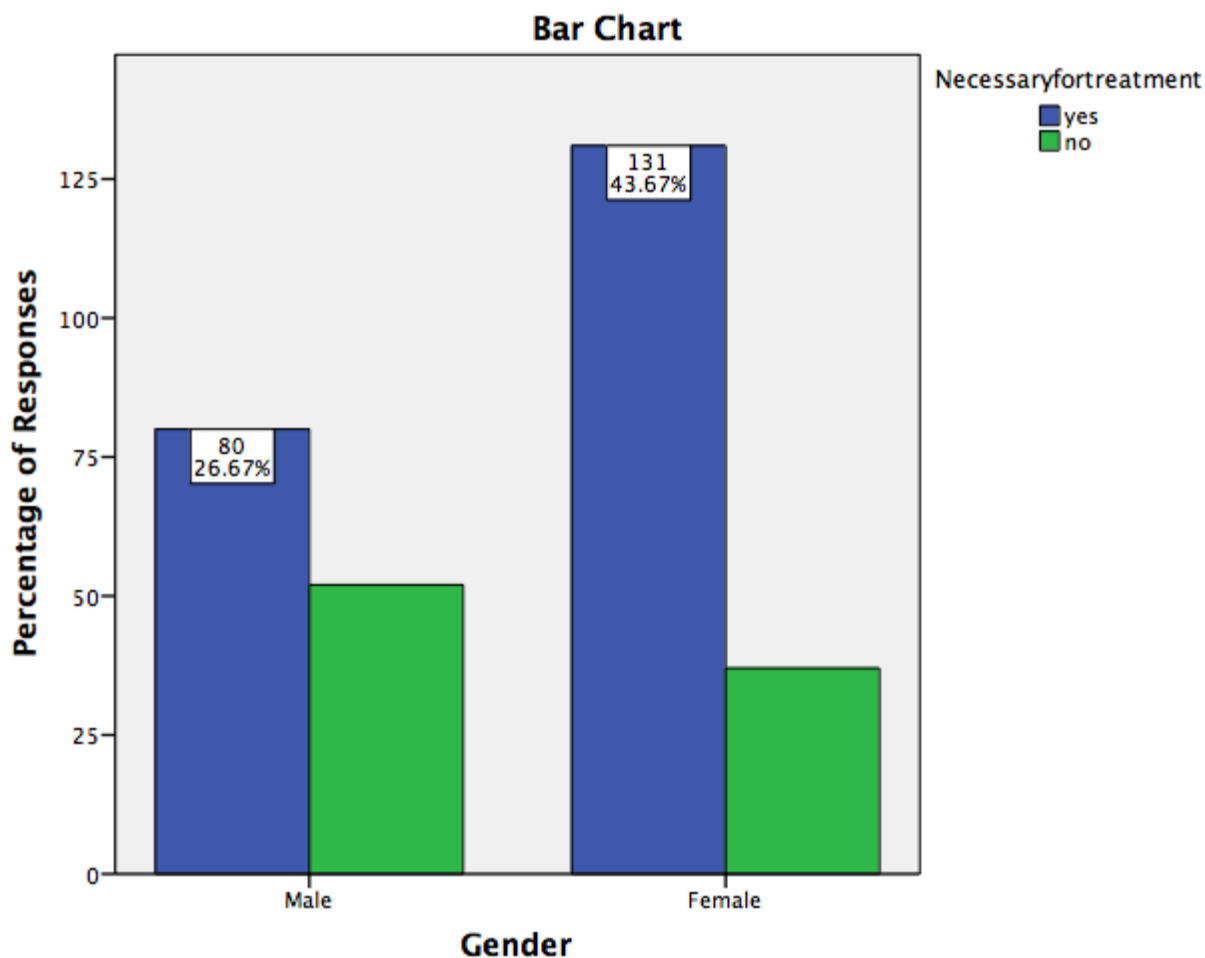


Figure 15: Bar graph represents the association between gender and the opinion regarding the necessity of taking photographs during orthodontic treatment. X axis depicts the gender and Y axis represents the number of responses from patients undergoing treatment. Majority of the female patients were of the opinion that dental photography was necessary in orthodontic treatment. Pearson Chi square value -0.001(<0.05) hence, statistically significant.

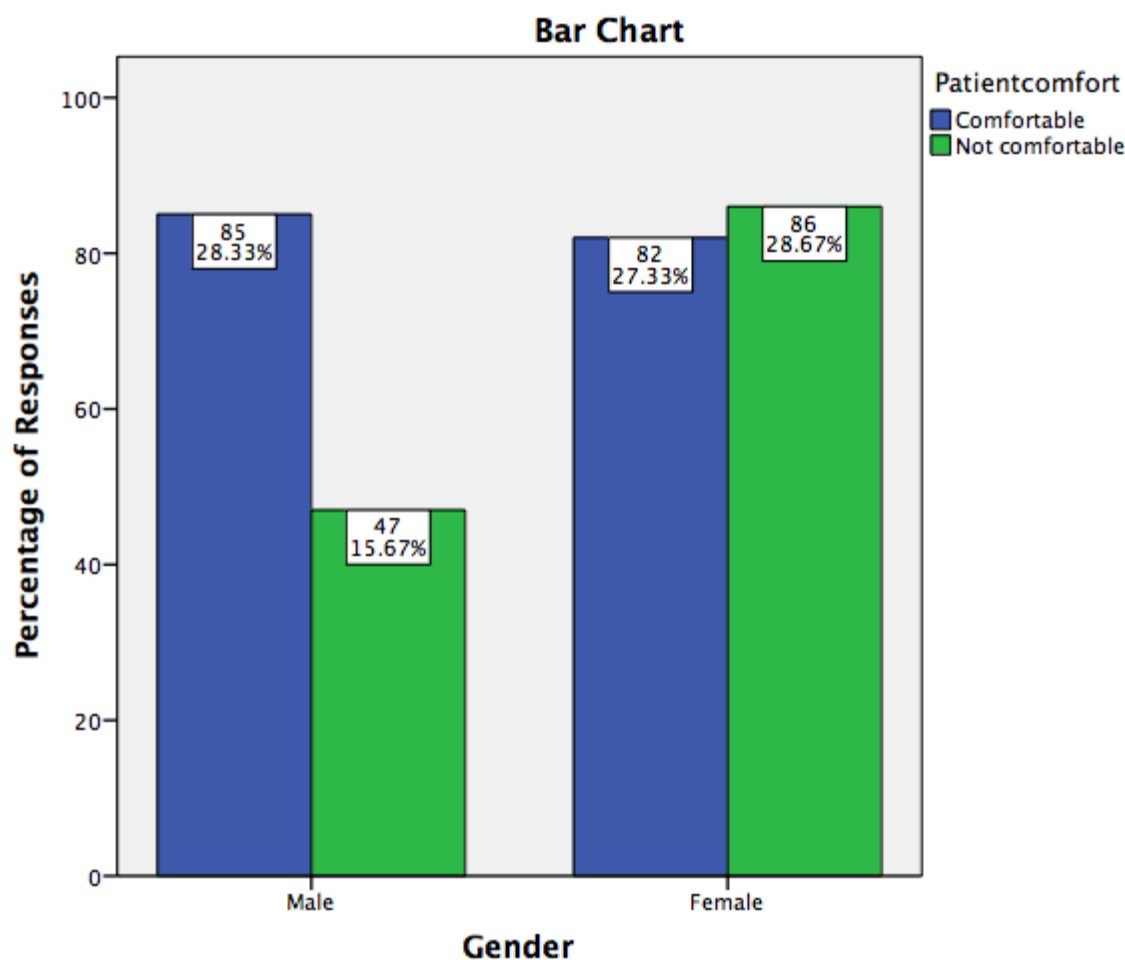


Figure 16: Bar graph depicts the gender distribution of different responses obtained regarding the comfort of the patients with photographs being taken during the treatment. X axis denotes the gender of the patient. Y axis denotes the number of patients .(Chi square test, p value-0.00) (<0.05) hence statistically significant. Majority of female patients have responded that they were uncomfortable with the photographs being taken during the treatment.

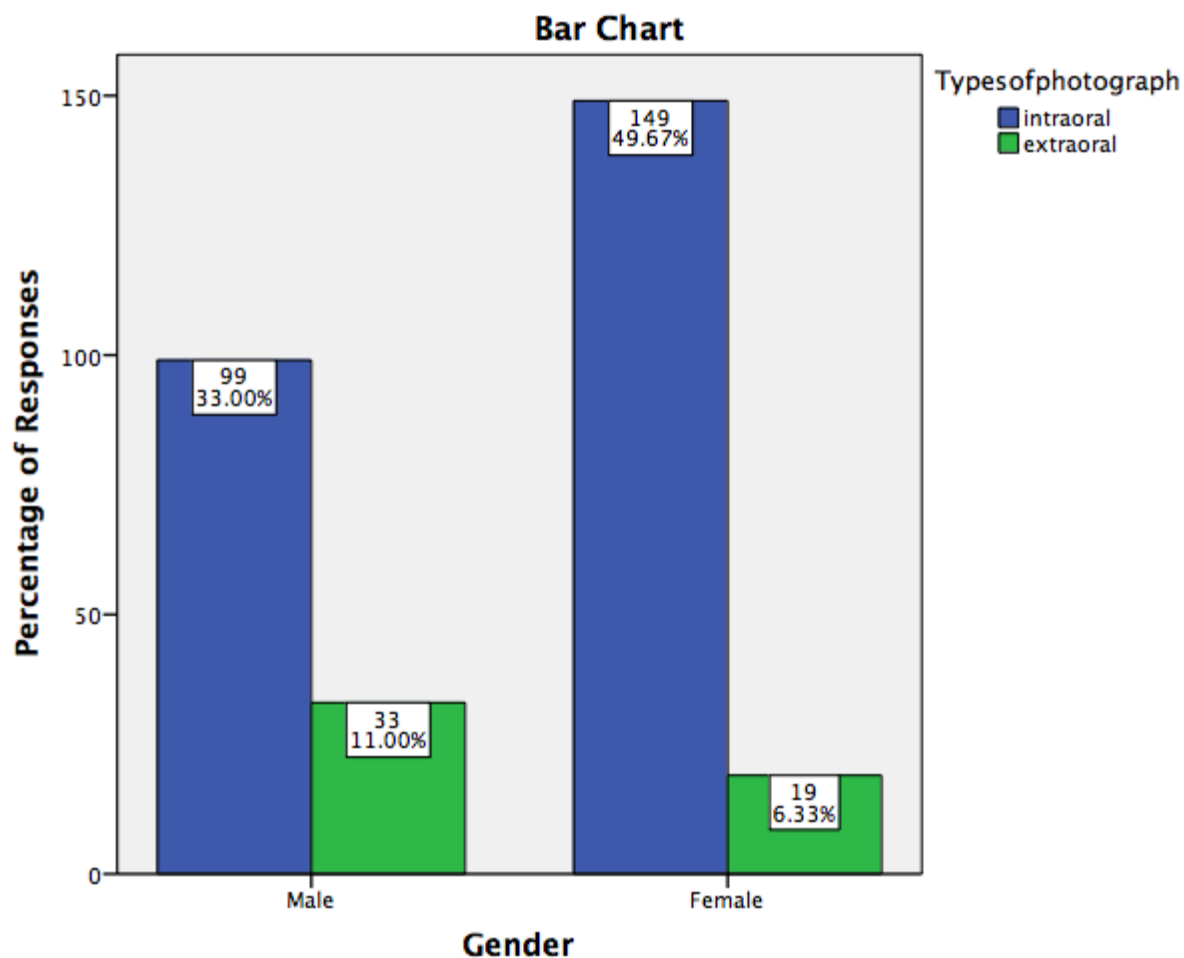


Figure 17: Bar graph represents the association between gender and the opinion regarding the type of photography that was most uncomfortable during orthodontic treatment. X axis depicts the gender and Y axis represents the number of responses from patients undergoing treatment. Majority of the female patients were of the opinion that intra oral photography was uncomfortable compared to extra oral photography during orthodontic treatment. Pearson Chi square test, p value = 0.002 (<0.05) hence, statistically significant.

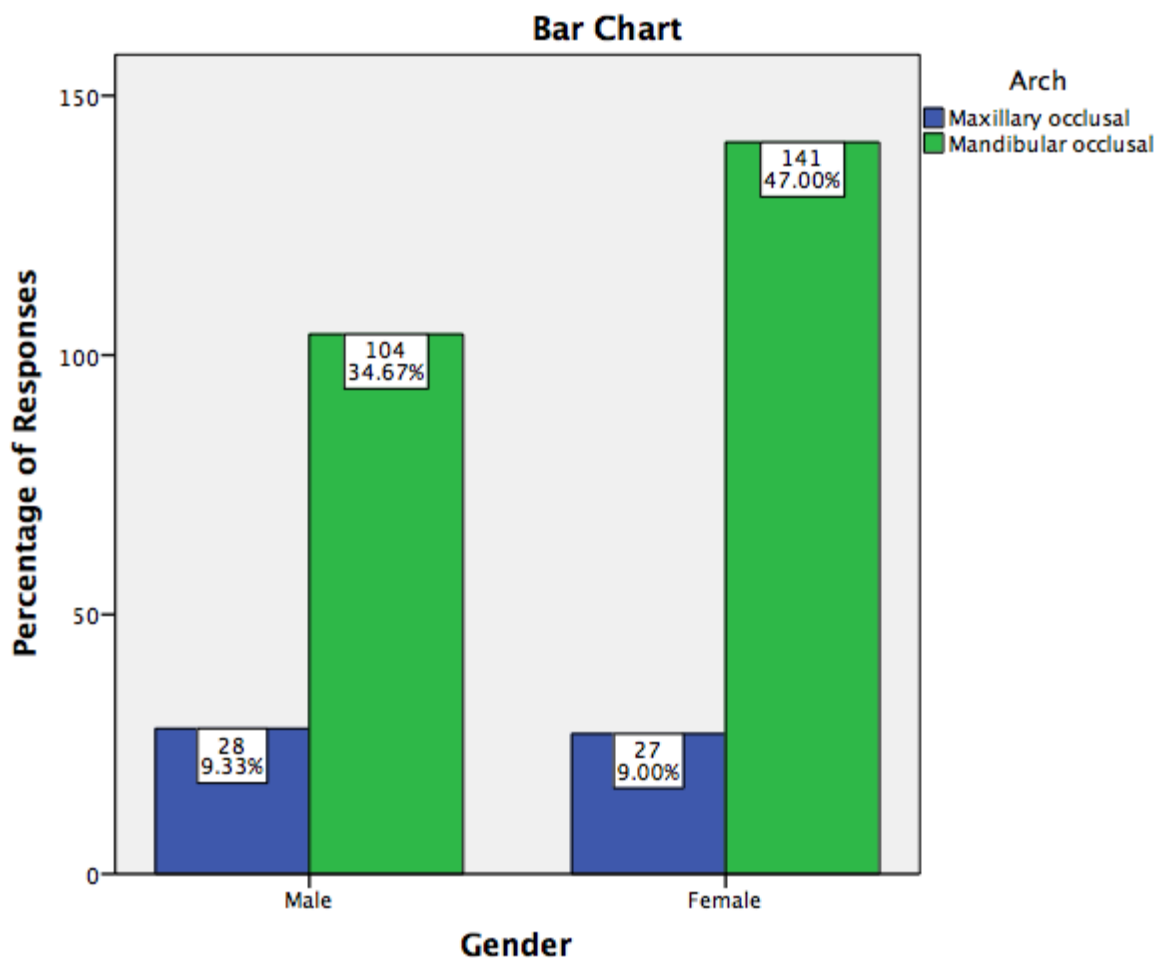


Figure 18: Bar graph represents the association between gender and the opinion regarding the arch that was most uncomfortable when being photographed during orthodontic treatment. X axis depicts the gender and Y axis represents the number of responses from patients undergoing treatment. Majority of the female patients were of the opinion that mandibular arch was the most uncomfortable compared to maxillary arch when being photography during orthodontic treatment. Pearson Chi square test, p value -0.253(>0.05) hence, statistically not significant .

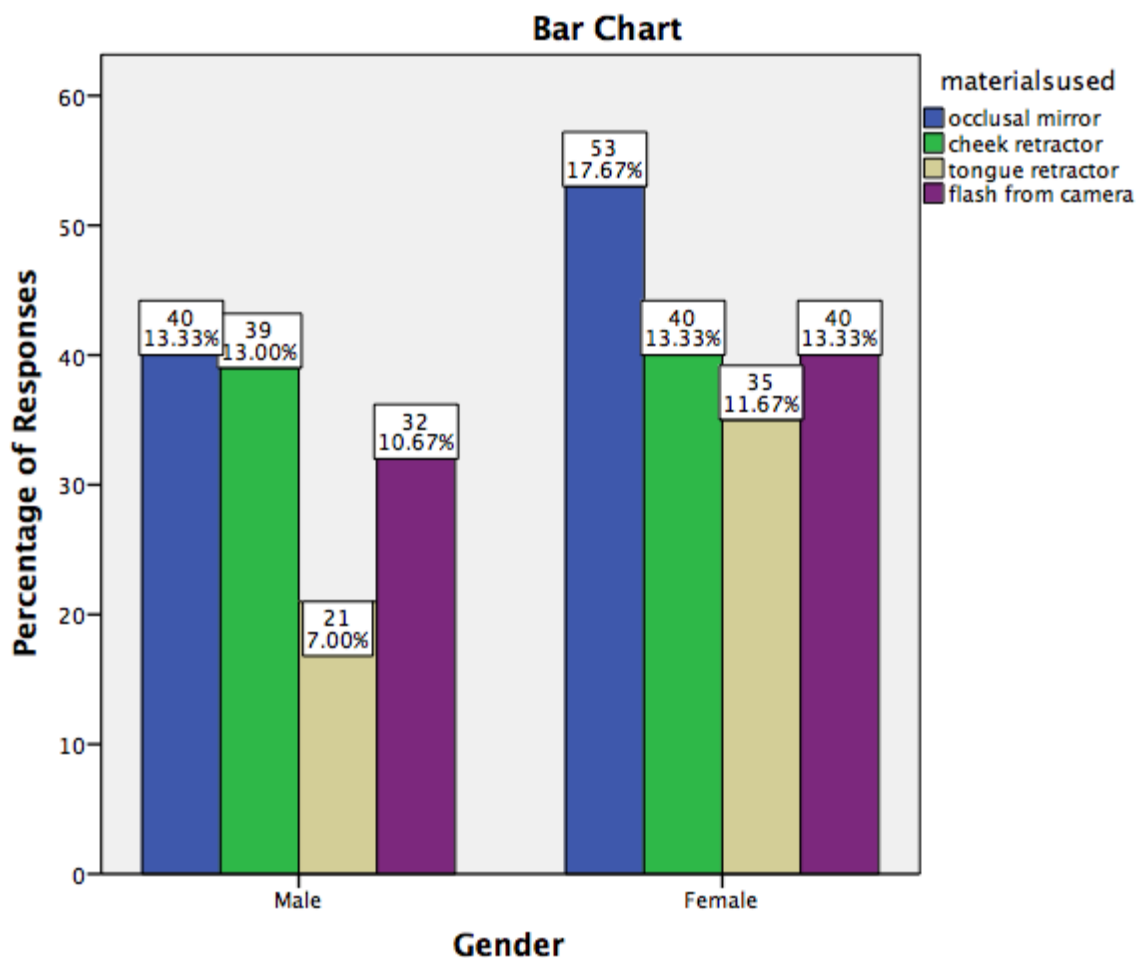


Figure 19: Bar graph depicts the gender distribution of different responses obtained regarding the opinion on the materials used during photography. X axis denotes the gender of the patient. Y axis denotes the number of patients. Chi square test, p value-0.588 (>0.05) hence statistically not significant. Majority of female patients have responded that occlusal mirrors were the most uncomfortable material compared to retractors and flash of the camera.

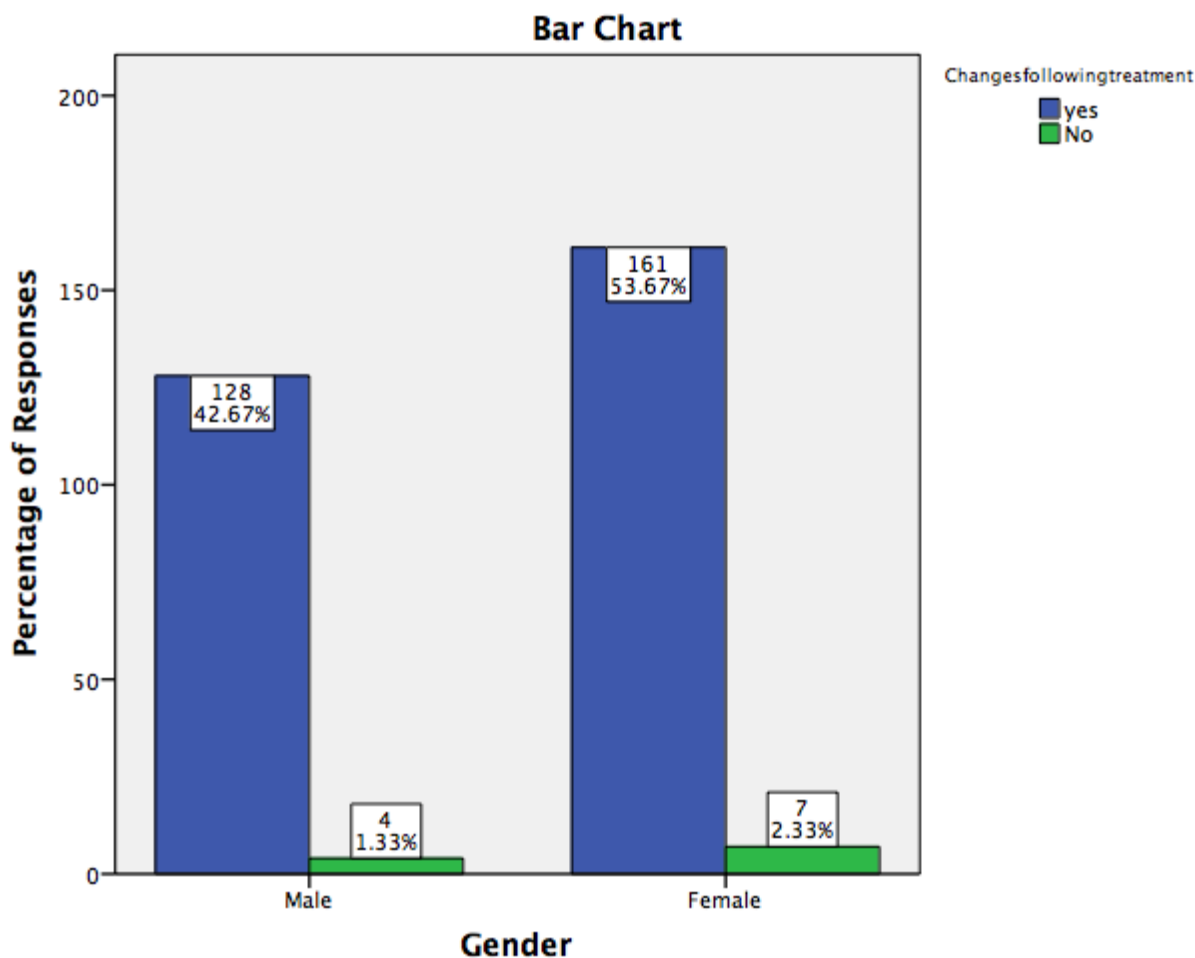


Figure 20: Bar graph represents the association between gender and the opinion regarding the treatment outcome from photographs taken during orthodontic treatment. X axis depicts the gender and Y axis represents the number of responses from patients undergoing treatment. Majority of the female patients were of the opinion that they could appreciate the outcome of the treatment from pre treatment and post treatment photographs taken during orthodontic treatment. Pearson Chi square test, p value -0.603(>0.05) hence, statistically not significant .

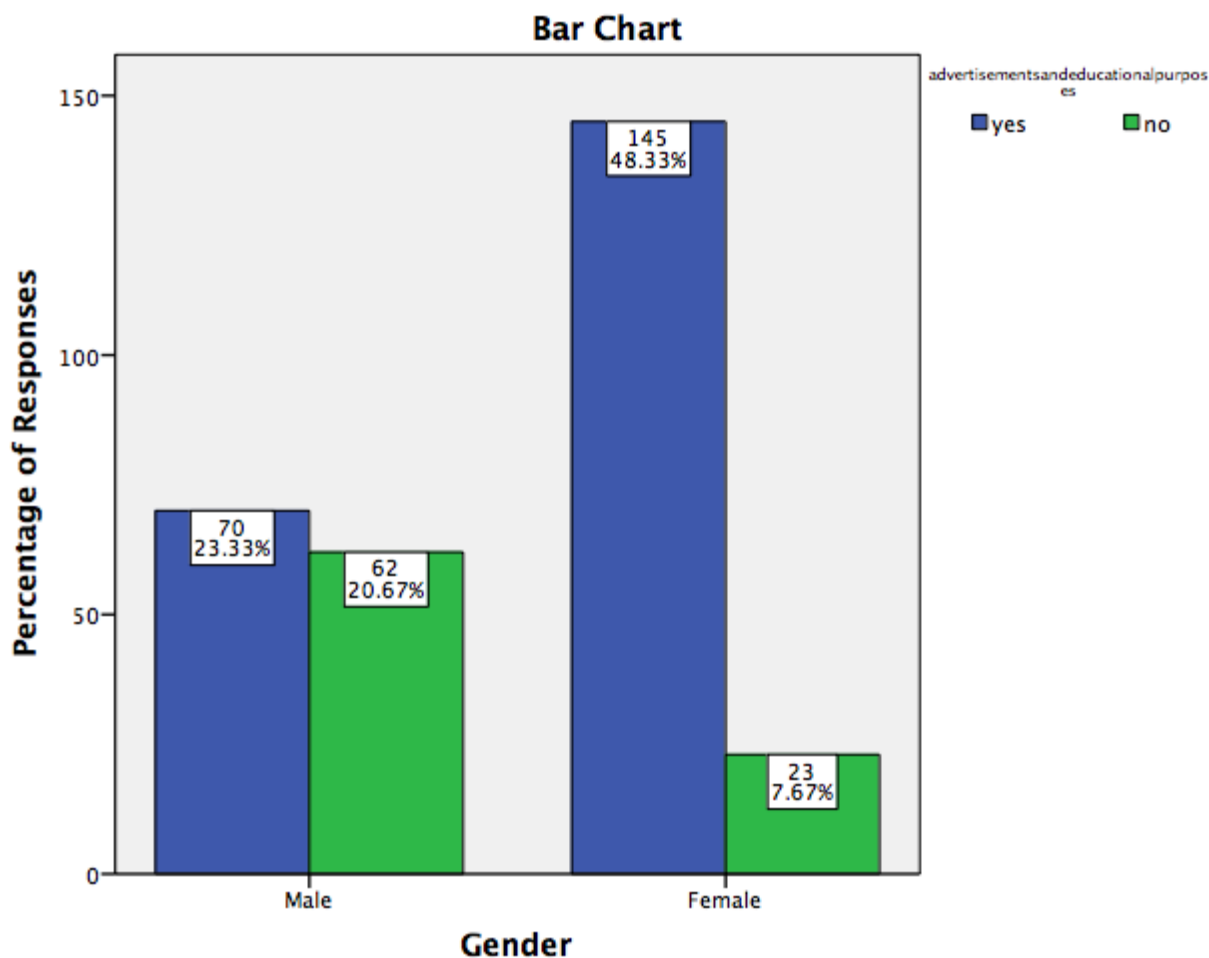


Figure 21: Bar graph depicts the gender distribution of different responses obtained regarding the opinion on their photos being used for advertisements or educational purposes. X axis denotes the gender of the patient. Y axis denotes the number of patients. Chi square test, p value-0.00 (<0.05) hence statistically significant. Majority of female patients gave consent to use their photographs for advertisements or educational purposes.

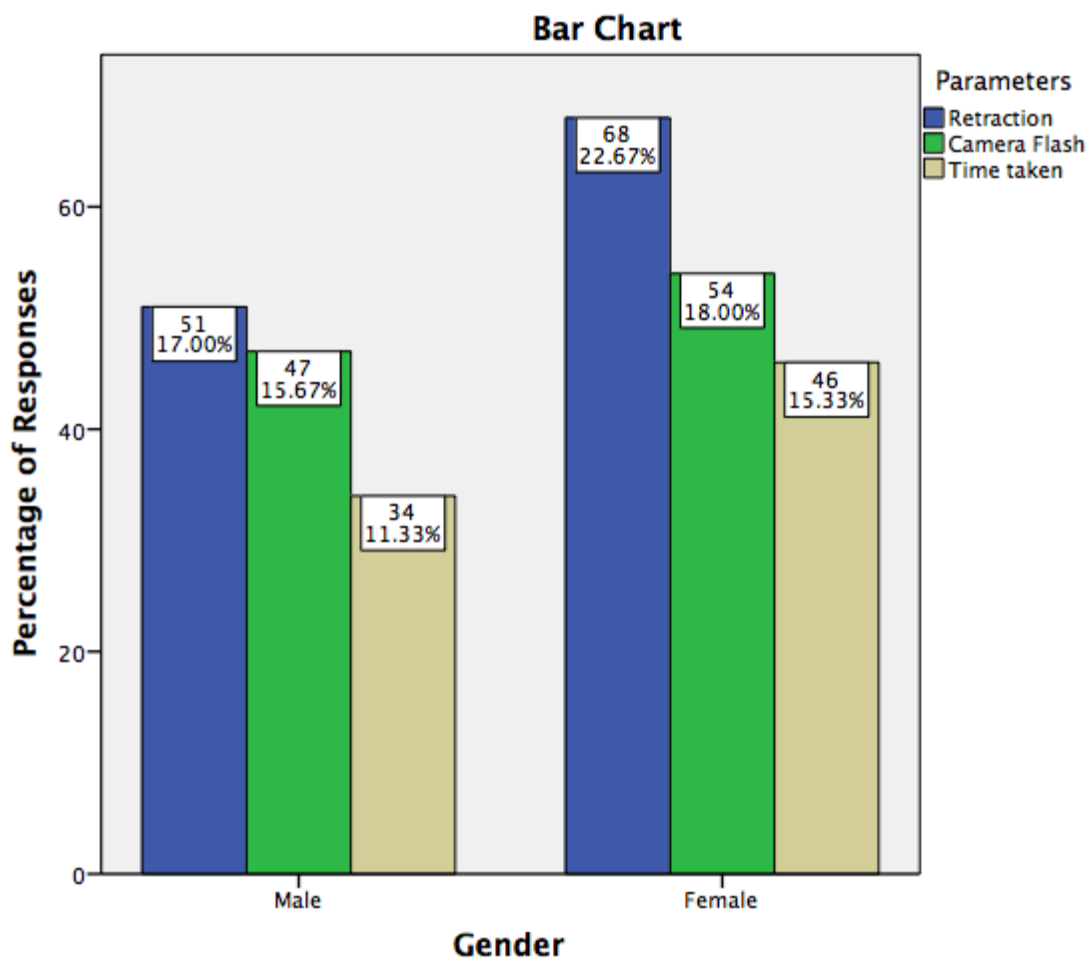


Figure 22: Bar graph represents the association between gender and the opinion regarding the parameters that need to be improved for better comfort during photography. X axis depicts the gender and Y axis represents the number of responses from patients undergoing treatment. Majority of the female patients were of the opinion that retractors used during photography was a parameter that needed to be improved to reduce the discomfort. Chi-square test, p value -0.819(>0.05) hence, statistically not significant.

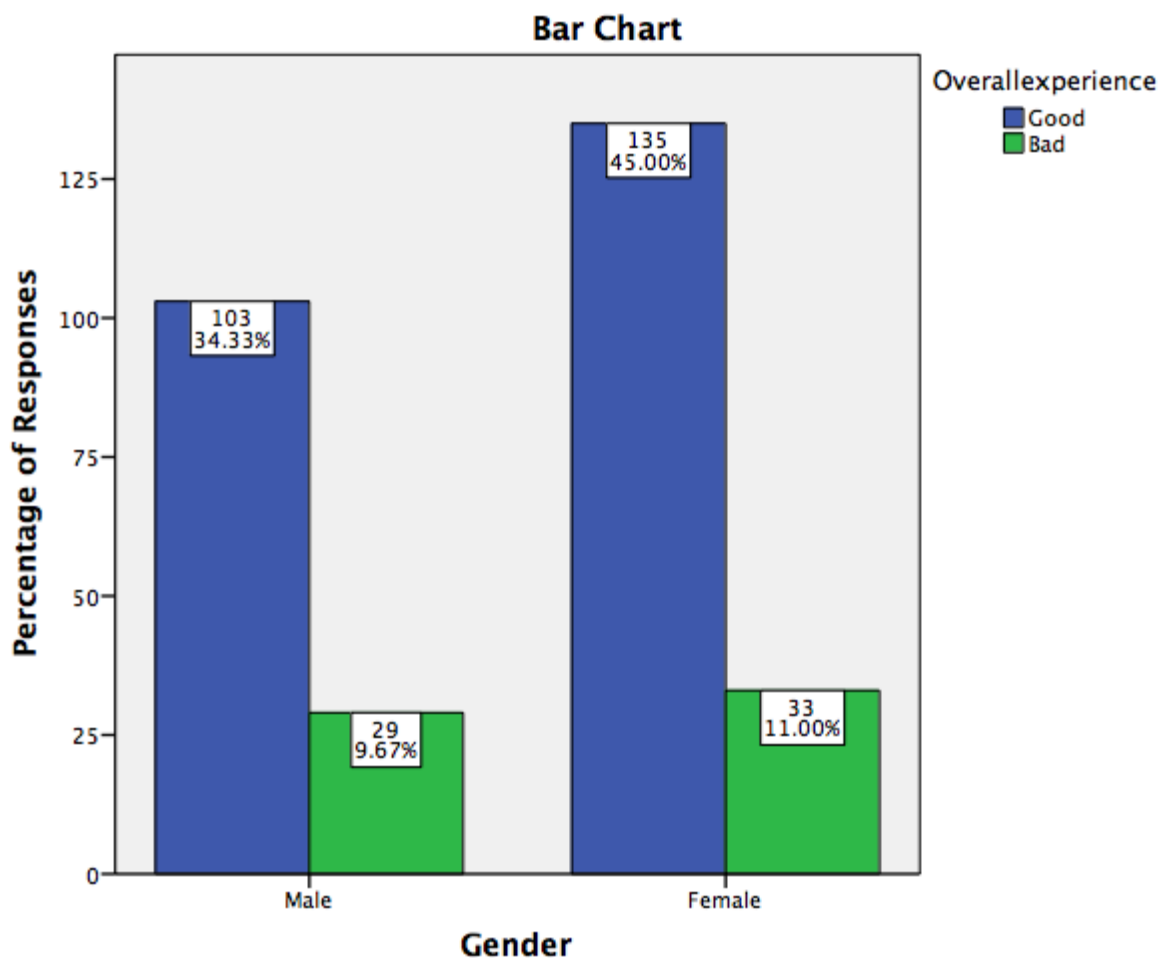


Figure 23: Bar graph represents the association between gender and patients overall experience about the photographs being taken during orthodontic treatment . X axis depicts the gender and Y axis represents the number of responses from patients undergoing treatment. Majority of the female patients responded that they had a good experience. Pearson Chi-square test, p value -0.621(>0.05) hence, statistically not significant .