

# Analysis of Site of Perforation during Access Preparation - A Retrospective Study

Running title: Analysis of perforation site during access preparation

**Priadarsini T**

*Saveetha dental college and hospitals*

*Saveetha Institute of Medical and Technical Sciences*

*Saveetha University*

*Chennai - 77*

*Email: dachupria.rsk@gmail.com*

**Sowmya K**

*Senior lecturer*

*Department of Conservative Dentistry and Endodontics*

*Saveetha Dental College and Hospitals*

*Saveetha Institute of Medical and Technical Sciences Saveetha University*

*Chennai-77*

*Email: sowmyak.sdc@saveetha.com*

**DhanrajGanapathy**

*Professor*

*Department of Prosthodontics*

*Saveetha Dental College and Hospitals*

*Saveetha Institute of Medical and Technical Sciences Saveetha University*

*Chennai-77*

*Email: dhanraj@saveetha.com*

**Corresponding author:**

**Sowmya K**

*Senior lecturer*

*Department of Conservative Dentistry and Endodontics*

*Saveetha Dental College and Hospitals*

*Saveetha Institute of Medical and Technical Sciences, Saveetha University*

*162, PH Road , Chennai-600077*

*Tamilnadu, India*

*Email: sowmyak.sdc@saveetha.com*

**Article Info****Volume 83****Page Number: 2150 - 2259****Publication Issue:****July-August 2020****Article History****Article Received: 06 June 2020****Revised: 29 June 2020****Accepted: 14 July 2020****Publication: 25 July 2020****Abstract:**

Perforation results in communication between the root canal walls and the periodontal space. It is commonly caused by operative procedural accidents or due to extensive caries, external and internal inflammatory root resorption. Perforations during a root canal treatment may increase the risk of failure for the involved tooth. The prognosis of a perforated tooth depends on factors like location and the size of the perforation, potential microbial colonization of the endodontic system, the time lapse between the occurrence of the perforation and repair, and the type of filling material used. For the long-term success of the root canal system, it is essential to emphasize disinfection and sterilization at the perforation site and the remaining root canal system. Nonsurgical management is possible with predictable prognosis if the right treatment is planned and executed. The aim of this study was to find the association of age, gender and tooth arch with the site of perforation during access cavity preparation. The data was collected from patients visiting Saveetha dental College for treatment. Totally 41 perforations were identified and treated completely. The data was entered in excel sheet and exported to IBM SPSS software version 20.0 and statistical analysis done. The number of perforations were higher in females and in the age group above 40 years, however no significant association was found for site of perforation with age and gender. Number of coronal perforations were more than furcal perforation and this association between tooth arch and site of perforation was found to be statistically significant ( $P$  value-  $0.006 < 0.05$ ; Chi square test). Proper knowledge of anatomy and principles of access cavity is essential to prevent these iatrogenic errors.

**Keywords:** Age; Coronal; Furcal; Perforation; Repair; Root canal treatment.

**INTRODUCTION:**

Perforation is characterized by a communication between the root canal system and the external tooth surface (Endodontists, 2003). It results in the destruction of the dentine root wall or floor along with the investing cementum. This communication compromises the health of the periradicular tissues and threatens the viability of the tooth. Perforation can be caused by a pathological process like extensive caries, external and internal inflammatory root resorption or an operating procedural accident (Kumar and Antony, 2018). Pathological perforations are found in routine chemical examination (Ramamoorthi, Nivedhitha and Divyanand, 2015; Ramanathan and Solete, 2015). Whereas iatrogenic perforation may occur during access cavity opening, root canal preparation or during post space preparation (Ravinthar and Jayalakshmi, 2018). Procedural operative errors may occur at any time in root canal

treatment which causes the treatment to fail (Rajendran *et al.*, 2019; Siddique and Jayalakshmi, 2019).

There are several factors that may predispose to iatrogenic perforations (Hussain *et al.*, 2018; R, Rajakeerthi and Ms, 2019). The presence of pulp stones, calcification, missed placed tooth, incorrect inclination in the arch - tipping or rotation, extension of caries, internal root resorption, misidentification of the root canal, and extra coronal restoration or intracoronary posts are factors that may make the root canal access difficult and predispose to root or furcal perforation (Noor, S Syed Shihaab and Pradeep, 2016; Teja, Ramesh and Priya, 2018; Arens and Torabinejad, 1996).

During the endodontic procedures the clinician must avoid and prevent these events, since they predispose to failure of root canal treatment (Bryan, Woollard and Mitchell, 1999). Successful root canal treatment

entails understanding the risk factors associated with root canal treatment failure (Manohar and Sharma, 2018; Nandakumar and Nasim, 2018; Teja and Ramesh, 2019).

The diagnosis of perforation is mostly based on the symptoms, clinical and radiographic examination. The classic symptoms are the sensitivity of the instrument introduction into the root canal and bleeding. Diagnosis of perforation can be assessed by direct observation of bleeding, indirect assessment of bleeding using a paper point, radiography, apex locator, symptomatic findings, using dental operating microscope and CBCT (Alhadainy, 1994).

Perforation needs to be diagnosed and treated early and appropriately to improve the prognosis of the tooth. Perforation may result in an inflammatory response causing the destruction of periodontal tissue and alveolar bone (Janani, Palanivelu and Sandhya, 2020; Jose and Subbaiyan, 2020; Teja, Ramesh and Priya, 2018). Depending on the severity of the injury, and possible chronic inflammatory reaction, it may cause the development of granulomatous tissue, proliferation of the epithelium, and, eventually, the development of a periodontal pocket (Yaltiriket *al.*, 2004).

Critical factors that contribute to successful management of perforation are size, time of repair, level and location, periodontal status of the tooth, access and visibility of the perforation and biocompatibility of perforation repair material (Fuss and Trope, 1996). Lack of understanding of perforations and their consequences, to the extent that could delay diagnosis and treatment, may cause problems ultimately leading to tooth loss.

The prognosis of endodontically treated teeth with perforations is dependent on the prevention of bacterial infection of the perforation site. The location of the perforation greatly influences the overall tooth prognosis (Gutmann and Lovdahl, 2010; Ng, Mann and Gulabivala, 2011). The aim of this present study is

to evaluate the association of site of perforation with age, gender and tooth arch.

## **MATERIALS AND METHODS :**

### **Study Design and setting:**

In this cross sectional study, the data of 31 patients who underwent treatment for perforation repair in Saveetha dental college were collected from dental records. At data extraction all information was anonymised and tabulated into a spreadsheet.

### **Ethical Approval**

The study was commenced after approval from the institutional review board (Ethical approval number : SDC/SIHEC/2020/DIASDATA/0619-0320).

### **Selection of study population:**

#### **Inclusion criteria:**

- Iatrogenic perforation
- Perforation during access cavity preparation
- Patients for whom perforation repair is complete.

#### **Exclusion criteria:**

- Other Iatrogenic errors like instrument separation
- Pathological perforation
- Root perforation

### **Subjects and Procedures:**

Data collected from June 2019 to March 2020 comprised 41 perforations from 31 patients who had undergone perforation repair. The following data retrieved from the dental records: Patient's age, gender and tooth number and type of perforation.

### **Statistical analysis:**

The statistical analysis was done using SPSS software version 20.0 (SPSS Inc., Chicago, IL, USA). Descriptive statistics (frequency and percentage) and inferential statistics (Chi Square test) were done. The results were presented in the form of graphs.

## **RESULTS AND DISCUSSION:**

This study included the data of perforation repair done in 41 teeth.

Most of the teeth that underwent perforation repair belonged to the age group >40 years (53.66%) and 46.34% belonged to <40 years age group [Figure 1].

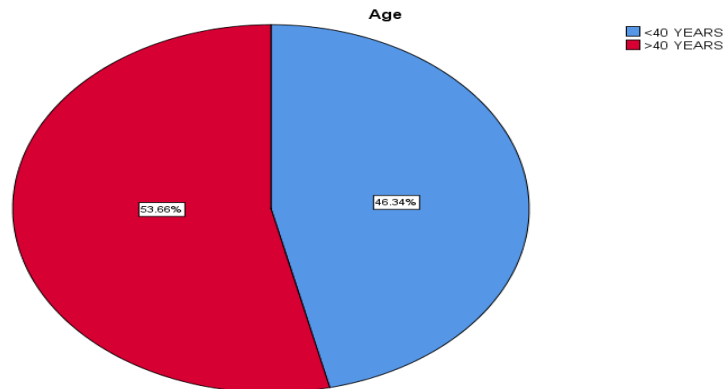


Figure 1: Pie chart representing the distribution of teeth that underwent perforation repair based on age. It is seen that 53.66% belonged to the >40 years (Red) age group while 46.34% belonged to the <40 years (Blue) age group.

56.10% of the total perforation was coronal

perforation while 43.90% were furcal perforation [Figure 2].

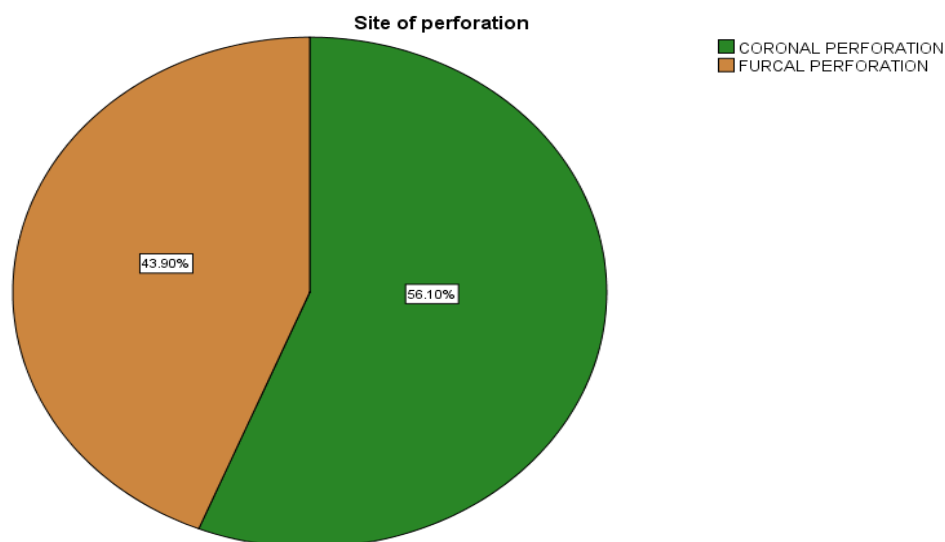


Figure 2 : Pie chart representing the distribution of teeth that underwent perforation repair based on site of perforation. It is observed that 56.10% was coronal perforation (Green) and 43.90% was furcal perforation (Brown).

53.66% of the teeth belonged to females and 46.34% to males [Figure 3].

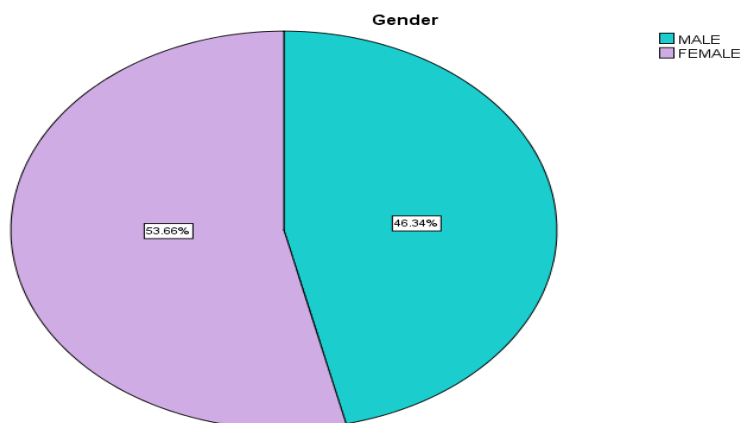


Figure 3 : Pie chart representing the distribution of teeth that underwent perforation repair based on gender. 53.66% of the teeth belonged to females (Purple) and 46.34% to males (Teal).

No significant association was found for site of Perforation with age and gender (P value >0.05) [Figures 4&5].

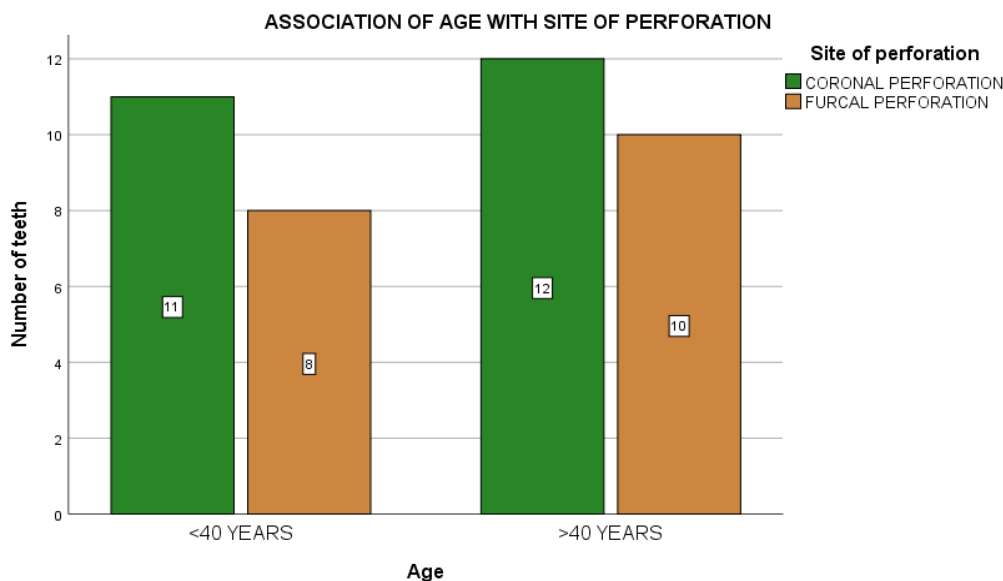


Figure 4 : Bar graph representing the association between age and site of perforation . X-axis denotes the age groups and Y-axis denotes the number of teeth. The number of coronal perforation (Green) was higher than furcal perforation (Brown) in both the age groups. This association between age and site of perforation was not statistically significant (P value- 0.829 >0.05; Chi square test).

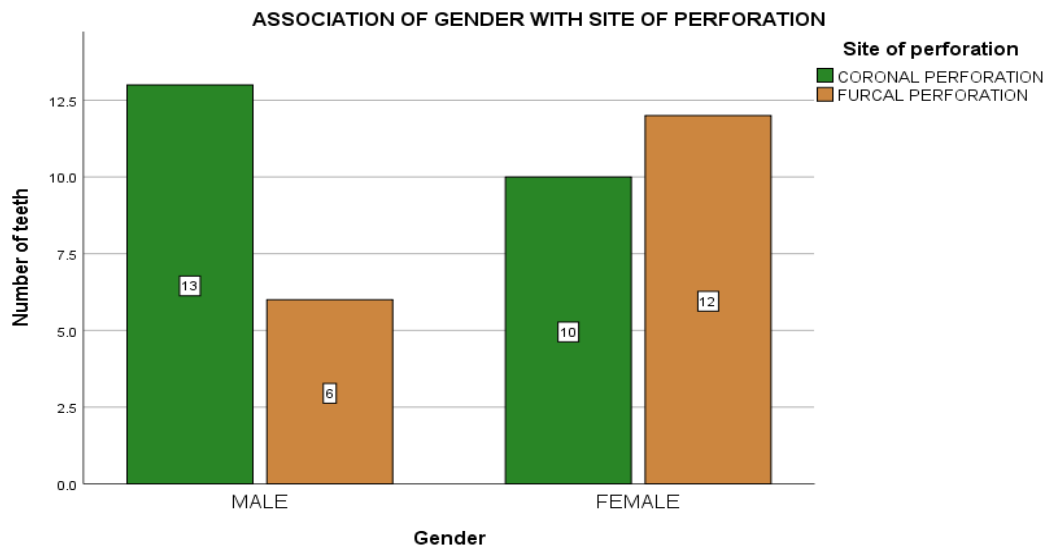


Figure 5 : Bar graph representing the association between gender and site of perforation . X-axis denotes the gender and Y-axis denotes the number of teeth. The number of coronal perforation (Green) was higher in males while furcal perforation (Brown) was higher in females. However, this association between gender and site of perforation was not statistically significant (P value- 0.139 >0.05; Chi square test).

The number of furcal perforation was higher in association between tooth arch and site of perforation mandible whereas coronal perforations (Green) were (P value- 0.006; Chi square test) [Figure 6]. higher in maxilla and there was a significant

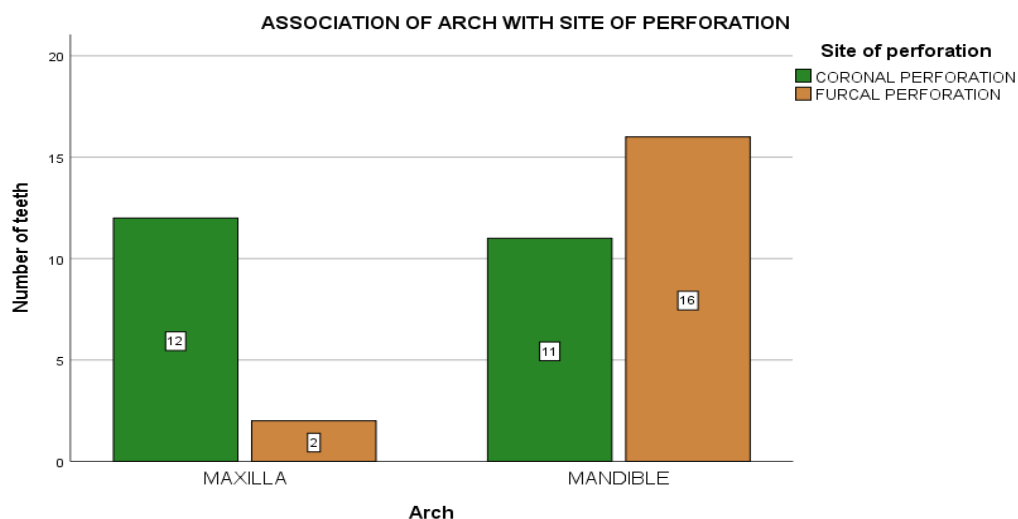


Figure 6 : Bar graph representing the association between tooth arch and site of perforation. X-axis denotes the tooth arch and Y-axis denotes the number of teeth. The number of furcal perforation (Brown) was higher in mandible whereas coronal perforations (Green) were higher in maxilla. There was a significant association between tooth arch and site of perforation (P value- 0.006 < 0.05; Chi square test).

It was seen in our study that perforation was more above 40 years of age, however no significant association was found between age and site of perforation [Figures 1&4]. Pulpal calcifications are more prevalent with age. One report found that 90% of the pulps of patients aged 45–63 exhibited pulpal calcifications present, compared with only 7% of pulps from patients aged 22–44 years (Sayegh and Reed, 1968). Calcified canals present a practical challenge to the clinician during root canal treatment as the risk of perforation is great and much care must be exercised when locating and instrumenting the canals (Ingle, 1986). Also, perforation in elderly people can compromise the healing as it takes a long time for the periodontal tissues to regenerate (Nikoloudakiet *al.*, 2014).

In our study, 56.10% of the total perforation were coronal perforation while 43.90% were furcal perforation [Figure 2]. An average 2% to 12% of endodontically treated cases have reported accidental furcal perforations (Seltzer *et al.*, 1967). Accidental furcal perforations do occur in approximately 2–12% of endodontically treated teeth that might have serious implications (Ingle, 1961; Seltzer *et al.*, 1967; Kerekes and Tronstad, 1979; Kvinnsland *et al.*, 1989; Farzaneh, Abitbol and Friedman, 2004). This perforation can act as an open channel encouraging bacterial entry either from root canal or periodontal tissues or both and elicits an inflammatory response resulting in fistula formation or bone resorption (Tsesis and Fuss, 2006). Coronal perforations occur coronally to the level of crestal bone and epithelial attachment with minimal damage to the supporting tissues and are easily accessible. Hence they have a good prognosis (Fuss and Trope, 1996). When lateral or furcal perforation occurs, there might be overgrowth of gingival epithelium towards the perforation site worsening prognosis of the tooth (Tsesis and Fuss, 2006).

Although perforations were slightly higher in females than males, no significant association was found between gender and site of perforation [Figures 3&5]. Gender is an important parameter to be considered as females have shown to have prolonged inflammation after perforation repair than men (Gorniet *al.*, 2016).

In a study by Haji- Hassani *et al.*, maxilla was more involved by the iatrogenic mistakes (Haji-Hassani, Bakhshi and Shahabi, 2015). Whereas in our study, more perforations were found in mandible than maxilla and this association between tooth arch and site of perforation was found to be statistically significant ( $P$  value-  $0.006 < 0.05$ ; Chi square test) [Figure 6]. The significant complex curvature, configuration and variations of mandibular molar may pose technical difficulties for the clinician during endodontic treatment which may lead to perforation (Rosen, Nemcovsky and Tsesis, 2017).

The life of an endodontically treated tooth is associated with correct diagnosis and treatment planning, root canal shaping, sanitization, sealing, and, lastly, tooth rehabilitation. The success of perforation repair depends on several factors including the material used for repair, perforation extent and location, time between diagnosis and treatment, presence of contamination, experience of the clinician, presence of preoperative lesions, communication of the perforation with the oral environment, and type and quality of the final restoration. The perforation repair material should have good physicochemical and biological properties, proper sealing capacity, antimicrobial activity and osteogenic potential. MTA has been the most widely indicated material for management of perforations. Histologically, the lateral and furcal perforations repaired with MTA, are found to have mineralized tissue over the material. Clinical studies have shown that MTA appears to provide a biocompatible and long-term effective seal for root perforation, with a higher success rate (Moreinis, 1979).



However, no cure can be better than prevention. Prevention of iatrogenic errors can be achieved by proper preoperative evaluation which includes consideration of the position of roots, relationship of crown to the root, rotation of the tooth in the arch, relationship of incisal edge or cusp tip to the long axis of the tooth.

## CONCLUSION:

Within the limitations of the study, tooth arch had an association with the site of perforation, with mandible having the highest number of perforations. Age and gender had no influence on the site of perforation. With proper anatomic knowledge and magnification, iatrogenic errors can be avoided. Perforation during operative procedures should be prevented. Diagnosis and immediate sealing, intensity of aggression, control of contamination, relationship to crestal bone and epithelial attachment are factors that have an impact on the prognosis.

## AUTHOR CONTRIBUTIONS:

Priadarsini T, Dr Sowmya K were the main contributors for the concept, design, literature analysis, workshop discussions, drafting and revising the manuscript. Dr. Sowmya K and Dr. Dhanraj Ganapathy contributed to drafting and revising the manuscript. All authors gave final approval of the version to be published.

## CONFLICTS OF INTEREST:

There are no conflicts of interest.

## REFERENCE:

1. Alhadainy, H. A. (1994) 'Root perforations. A review of literature', *Oral surgery, oral medicine, and oral pathology*, 78(3), pp. 368–374.
2. Arens, D. E. and Torabinejad, M. (1996) 'Repair of furcal perforations with mineral trioxide aggregate: two case reports', *Oral surgery, oral medicine, oral pathology, oral radiology, and endodontics*, 82(1), pp. 84–88.
3. Bryan, E. B., Woollard, G. and Mitchell, W. C. (1999) 'Nonsurgical repair of furcal perforations: a literature review', *General dentistry*, 47(3), pp. 274–8; quiz 279–80.
4. Endodontists, A. A. O. (2003) 'Glossary of Endodontic Terms', *Chicago: American Association of Endodontists*.
5. Farzaneh, M., Abitbol, S. and Friedman, S. (2004) 'Treatment outcome in endodontics: the Toronto study. Phases I and II: Orthograde retreatment', *Journal of endodontia*, 30(9), pp. 627–633.
6. Fuss, Z. and Trope, M. (1996) 'Root perforations: classification and treatment choices based on prognostic factors', *Endodontics & dental traumatology*, 12(6), pp. 255–264.
7. Gorni, F. G. *et al.* (2016) 'Patient and Clinical Characteristics Associated with Primary Healing of Iatrogenic Perforations after Root Canal Treatment: Results of a Long-term Italian Study', *Journal of endodontia*, 42(2), pp. 211–215.
8. Gutmann, J. L. and Lovdahl, P. E. (2010) *Problem Solving in Endodontics - E-Book: Prevention, Identification and Management*. Elsevier Health Sciences.
9. Haji-Hassani, N., Bakhshi, M. and Shahabi, S. (2015) 'Frequency of Iatrogenic Errors through Root Canal Treatment Procedure in 1335 Charts of Dental Patients', *Journal of international oral health : JIOH*, 7(Suppl 1), pp. 14–17.
10. Hussainy, S. N. *et al.* (2018) 'Clinical performance of resin-modified glass ionomer cement, flowable composite, and polyacid-modified resin composite in noncarious cervical lesions: One-year follow-up', *Journal of conservative dentistry: JCD*, 21(5), pp. 510–515.
11. Ingle, J. I. (1961) 'A standardized endodontic technique utilizing newly designed instruments and filling materials', *Oral surgery, oral medicine, and oral pathology*, 14, pp. 83–91.
12. Ingle, J. I. (1986) 'Geriatric endodontics', *The*



- Alpha omegan*, 79(4), pp. 47–53.
13. Janani, K., Palanivelu, A. and Sandhya, R. (2020) 'Diagnostic accuracy of dental pulse oximeter with customized sensor holder, thermal test and electric pulp test for the evaluation of pulp vitality - An in vivo study', *Brazilian Dental Science*. doi: 10.14295/bds.2020.v23i1.1805.
  14. Jose, J. and Subbaiyan, H. (2020) 'Different Treatment Modalities followed by Dental Practitioners for Ellis Class 2 Fracture—A Questionnaire-based Survey', *The open dentistry journal*. opendentistryjournal.com. Available at: <https://opendentistryjournal.com/VOLUME/14/PAGE/59/FULLTEXT/>.
  15. Kerekes, K. and Tronstad, L. (1979) 'Long-term results of endodontic treatment performed with a standardized technique', *Journal of endodontia*, 5(3), pp. 83–90.
  16. Kumar, D. and Antony, S. (2018) 'Calcified Canal and Negotiation-A Review', *Research Journal of Pharmacy and Technology*. A & V Publications, 11(8), pp. 3727–3730.
  17. Kvinnsland, I. *et al.* (1989) 'A clinical and roentgenological study of 55 cases of root perforation', *International endodontic journal*, 22(2), pp. 75–84.
  18. Manohar, M. P. and Sharma, S. (2018) 'A survey of the knowledge, attitude, and awareness about the principal choice of intracanal medicaments among the general dental practitioners and ...', *Indian journal of dental research: official publication of Indian Society for Dental Research*. ijdr.in. Available at: <http://www.ijdr.in/article.asp?issn=0970-9290;year=2018;volume=29;issue=6;spage=716;epage=720;aulast=Manohar>.
  19. Moreinis, S. A. (1979) 'Avoiding perforation during endodontic access', *Journal of the American Dental Association*, 98(5), pp. 707–712.
  20. Nandakumar, M. and Nasim, I. (2018) 'Comparative evaluation of grape seed and cranberry extracts in preventing enamel erosion: An optical emission spectrometric analysis', *Journal of conservative dentistry: JCD*, 21(5), pp. 516–520.
  21. Ng, Y.-L., Mann, V. and Gulabivala, K. (2011) 'A prospective study of the factors affecting outcomes of nonsurgical root canal treatment: part 1: periapical health', *International endodontic journal*, 44(7), pp. 583–609.
  22. Nikoloudaki, G. E. *et al.* (2014) 'A comparative in-vitro study of sealing ability of four different materials used in furcation perforation', *Open Journal of Stomatology*. Scientific Research Publishing, 2014. Available at: [https://www.scirp.org/html/3-1460411\\_48559.htm](https://www.scirp.org/html/3-1460411_48559.htm).
  23. Noor, S. S. S. E., S Syed Shihaab and Pradeep (2016) 'Chlorhexidine: Its properties and effects', *Research Journal of Pharmacy and Technology*, p. 1755. doi: 10.5958/0974-360x.2016.00353.x.
  24. Rajendran, R. *et al.* (2019) 'Comparative Evaluation of Remineralizing Potential of a Paste Containing Bioactive Glass and a Topical Cream Containing Casein Phosphopeptide-Amorphous Calcium Phosphate: An in Vitro Study', *Pesquisa brasileira em odontopediatria e clinica integrada*. SciELO Brasil, 19. Available at: [http://www.scielo.br/scielo.php?pid=S1983-46322019000100364&script=sci\\_arttext](http://www.scielo.br/scielo.php?pid=S1983-46322019000100364&script=sci_arttext).
  25. Ramamoorthi, S., Nivedhitha, M. S. and Divyanand, M. J. (2015) 'Comparative evaluation of postoperative pain after using endodontic needle and EndoActivator during root canal irrigation: A randomised controlled trial', *Australian endodontic journal: the journal of the Australian Society of Endodontology Inc*, 41(2), pp. 78–87.
  26. Ramanathan, S. and Solete, P. (2015) 'Cone-beam Computed Tomography Evaluation of Root Canal Preparation using Various Rotary Instruments: An in vitro Study', *The journal of contemporary*

- dental practice, 16(11), pp. 869–872.
27. Ravinthar, K. and Jayalakshmi (2018) ‘Recent Advancements in Laminates and Veneers in Dentistry’, *Research Journal of Pharmacy and Technology*, p. 785. doi: 10.5958/0974-360x.2018.00148.8.
  28. Rosen, E., Nemcovsky, C. E. and Tsesis, I. (eds) (2017) *Evidence-Based Decision Making in Dentistry: Multidisciplinary Management of the Natural Dentition*. Springer, Cham.
  29. R, R., Rajakeerthi, R. and Ms, N. (2019) ‘Natural Product as the Storage medium for an avulsed tooth – A Systematic Review’, *Cumhuriyet Dental Journal*, pp. 249–256. doi: 10.7126/cumudj.525182.
  30. Sayegh, F. S. and Reed, A. J. (1968) ‘Calcification in the dental pulp’, *Oral Surgery, Oral Medicine, Oral Pathology*, pp. 873–882. doi: 10.1016/0030-4220(68)90165-5.
  31. Seltzer, S. *et al.* (1967) ‘Endodontic failures—An analysis based on clinical, roentgenographic, and histologic findings: Part II’, *Oral surgery, oral medicine, and oral pathology*. Elsevier, 23(4), pp. 517–530.
  32. Siddique, R. and Jayalakshmi, S. (2019) ‘Assessment of Precipitate Formation on Interaction of Chlorhexidine with Sodium Hypochlorite, Neem, Aloevera and Garlic: An in vitro Study’, *Indian Journal of Public Health Research & Development*, 10(11). Available at: <http://search.ebscohost.com/login.aspx?direct=true&profile=ehost&scope=site&authtype=crawler&jrnl=09760245&AN=141274509&h=nNuUVrzpZf6vnC1nrfcvRj1QN3khmGV5%2F17jDV1ZLAtFI19vTZj7rmuzLPeAZC9gCJ%2BYul3NDLw%2FXY3PB52%2BVw%3D%3D&crl=c>.
  33. Teja, K. V. and Ramesh, S. (2019) ‘Shape optimal and clean more’, *Saudi Endodontic Journal*. [saudiendodj.com](http://www.saudiendodj.com). Available at: <http://www.saudiendodj.com/article.asp?issn=1658-5984;year=2019;volume=9;issue=3;spage=235;epage=236;aulast=Teja>.
  34. Teja, K. V., Ramesh, S. and Priya, V. (2018) ‘Regulation of matrix metalloproteinase-3 gene expression in inflammation: A molecular study’, *Journal of conservative dentistry: JCD*, 21(6), pp. 592–596.
  35. Tsesis, I. and Fuss, Z. (2006) ‘Diagnosis and treatment of accidental root perforations’, *Endodontic Topics*, 13(1), pp. 95–107.
  36. Yaltirik, M. *et al.* (2004) ‘Reactions of connective tissue to mineral trioxide aggregate and amalgam’, *Journal of endodontia*, 30(2), pp. 95–99.